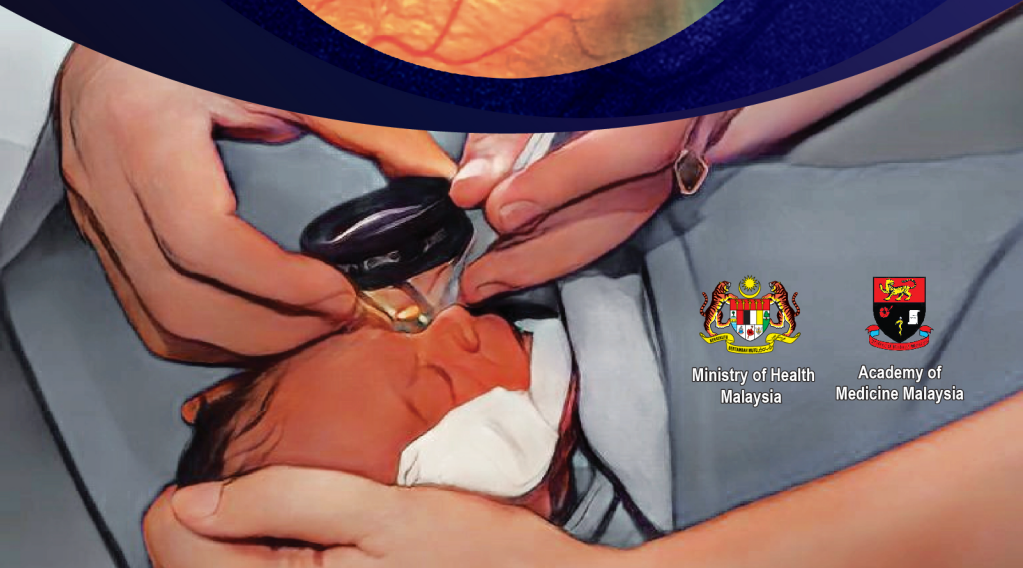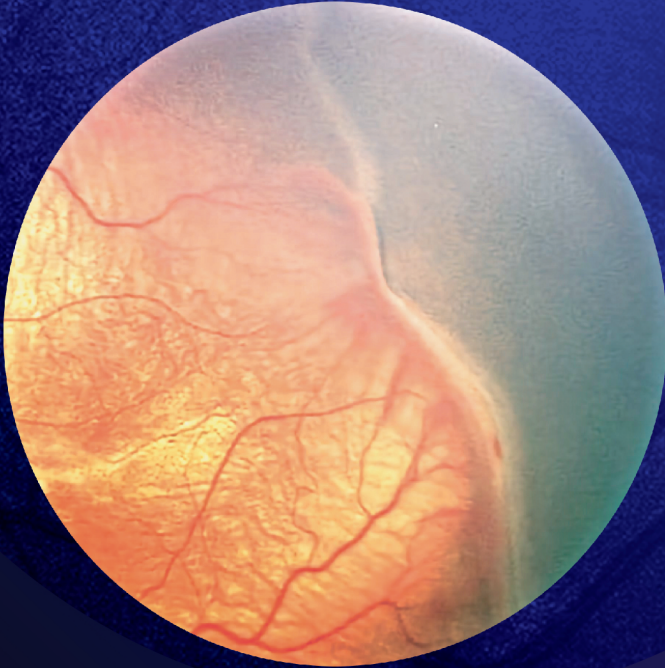


CLINICAL PRACTICE GUIDELINES

**MANAGEMENT OF**  
**RETINOPATHY OF PREMATURITY**  
*(Second Edition)*



Ministry of Health  
Malaysia



Academy of  
Medicine Malaysia

**Published by:**

Malaysia Health Technology Assessment Section (MaHTAS)  
Medical Development Division, Ministry of Health Malaysia  
Level 4, Block E1, Precinct 1  
Federal Government Administrative Centre  
62590 Putrajaya, Malaysia

**Copyright**

The copyright owner of this publication is MaHTAS. Content may be reproduced in any number of copies and in any format or medium provided that a copyright acknowledgement to MaHTAS is included and the content is not changed, not sold, or used to promote or endorse any product or service, and not used in an inappropriate or misleading context.

**e ISBN:** 978-967-2887-65-2

Available on the following websites:

<http://www.moh.gov.my>

<http://www.acadmed.org.my>

Also available as an app for Android and IOS platforms: MyMaHTAS

**STATEMENT OF INTENT**

These clinical practice guidelines (CPG) are meant to be guides for clinical practice, based on the best available evidence at the time of development. Adherence to these guidelines may not necessarily guarantee the best outcome in every case. Every healthcare provider is responsible for the management of his/her unique patient based on the clinical picture presented by the patient and the management options available locally.

## UPDATING THE CPG

These guidelines were issued in 2023 and will be reviewed in a minimum period of four years (2027) or **sooner if there is a need to do so**. When it is due for updating, the Chairman of the CPG or National Advisor of the related specialty will be informed about it. A discussion will be done on the need for a revision including the scope of the revised CPG. A multidisciplinary team will be formed and the latest systematic review methodology used by MaHTAS will be employed. Every care is taken to ensure that this publication is correct in every detail at the time of publication. However, in the event of errors or omissions, corrections will be published in the web version of this document, which is the definitive version at all times. This version can be found on the websites mentioned above.

## TABLE OF CONTENTS

| No.       | Title   | Page      |
|-----------|---|-----------|
|           | Levels of Evidence and Formulation of Recommendation                                  | i         |
|           | Key Recommendations   | ii        |
|           | Guidelines Development and Objectives   | iii       |
|           | Development Group   | vi        |
|           | Review Committee  | vii       |
|           | External Reviewers  | viii      |
|           | Algorithm 1. Screening and Treatment of Retinopathy<br>of Prematurity                 | ix        |
|           | Algorithm 2. Follow-Up of Retinopathy of Prematurity                                  | x         |
| <b>1.</b> | <b>INTRODUCTION</b>   | <b>1</b>  |
| <b>2.</b> | <b>RISK FACTORS</b>   | <b>2</b>  |
| <b>3.</b> | <b>IDENTIFICATION AND SCREENING OF INFANTS AT RISK</b>                                | <b>4</b>  |
|           | 3.1 Screening Criteria  | 4         |
|           | 3.2 Counselling   | 5         |
|           | 3.3 Preparation for Screening   | 6         |
|           | 3.4 Screening Methods   | 7         |
| <b>4.</b> | <b>CLASSIFICATION</b>   | <b>9</b>  |
| <b>5.</b> | <b>NATURAL COURSE OF DISEASE</b>  | <b>10</b> |
| <b>6.</b> | <b>TREATMENT</b>  | <b>12</b> |
|           | 6.1 Indication of Treatment   | 12        |
|           | 6.2 Optimum Timing for Treatment  | 12        |
|           | 6.3 Options for Treatment   | 13        |
|           | 6.3.1 Laser photocoagulation  | 13        |
|           | 6.3.2 Intravitreal anti-vascular endothelial<br>growth factor                         | 14        |
|           | 6.3.3 Cryotherapy   | 17        |
|           | 6.3.4 Vitreoretinal surgery   | 17        |
|           | 6.3.5 Adjunctive treatment  | 18        |
|           | 6.4 Treatment in Aggressive Retinopathy of Prematurity                                | 19        |
|           | 6.5 Rescue Treatment  | 20        |
| <b>7.</b> | <b>MONITORING AND DISCHARGE CRITERIA FOR<br/>RETINOPATHY OF PREMATURITY SCREENING</b> | <b>21</b> |
| <b>8.</b> | <b>FOLLOW-UP</b>  | <b>23</b> |
| <b>9.</b> | <b>REHABILITATION</b>   | <b>25</b> |



## TABLE OF CONTENTS

| No.                | Title   | Page          |
|--------------------|---|---------------|
| <b>10.</b>         | <b>IMPLEMENTING THE GUIDELINES</b>  | <b>26</b>     |
| 10.1               | Facilitating and Limiting Factors   | 26            |
| 10.2               | Potential Resource Implication  | 26            |
|                    | <br><b>REFERENCES</b>   | <br><b>28</b> |
| <b>Appendix 1</b>  | Example of Search Strategy  | 32            |
| <b>Appendix 2</b>  | Clinical Questions  | 33            |
| <b>Appendix 3</b>  | Optimum Timing for First Retinopathy of Prematurity Screening                           | 35            |
| <b>Appendix 4</b>  | Alternative Dilating Regimes  | 36            |
| <b>Appendix 5</b>  | Summary of Key Components of International Classification                               | 39            |
| <b>Appendix 6</b>  | Features of Retinopathy of Prematurity  | 42            |
| <b>Appendix 7</b>  | Indications of Treatment  | 46            |
| <b>Appendix 8</b>  | Laser Photocoagulation in Retinopathy of Prematurity                                    | 47            |
| <b>Appendix 9</b>  | Types and Properties of Anti-Vascular Endothelial Growth Factor                         | 49            |
| <b>Appendix 10</b> | Procedure for Intravitreal Anti-VEGF Injection  | 51            |
| <b>Appendix 11</b> | Special Educational Schools and Intergration Programmes for People with Visual Problems | 53            |
|                    | List of Abbreviations   | 56            |
|                    | Acknowledgement   | 57            |
|                    | Disclosure Statement  | 57            |
|                    | Source of Funding   | 57            |

## LEVELS OF EVIDENCE

| Level | Study design  |
|-------|---|
| I     | Properly powered and conducted randomised controlled trial; well-conducted systematic review or meta-analysis of homogeneous randomised controlled trials |
| II-1  | Well-designed controlled trial without randomisation  |
| II-2  | Well-designed cohort or case-control analysis study   |
| II-3  | Multiple time series, with or without the intervention; results from uncontrolled studies that yield results of large magnitude                           |
| III   | Opinions of respected authorities, based on clinical experience; descriptive studies or case reports; reports of expert committees                        |

*Source: U.S. Preventive Services Task Force. U.S. Preventive Services Task Force Procedure Manual. Rockville, MD: USPSTF; 2015.*

## FORMULATION OF RECOMMENDATION

In line with current development in CPG methodology, the CPG Unit of MaHTAS is in the process of adapting **Grading Recommendations, Assessment, Development and Evaluation (GRADE)** in its work process. The quality of each retrieved evidence and its effect size is carefully assessed/reviewed by the CPG Development Group. In formulating the recommendations, overall balances of the following aspects are considered in determining the strength of the recommendations:-

- overall quality of evidence
- balance of benefits versus harms
- values and preferences
- resource implications
- equity, feasibility and acceptability

## KEY RECOMMENDATIONS

The following recommendations were highlighted by the CPG Development Group (DG) as the key clinical recommendations that should be recognised for implementation.

## SCREENING AND DIAGNOSIS

- Screening for retinopathy of prematurity (ROP) should be done for infants with either one of the following criteria:
  - birth weight <1750 g
  - gestational age <34 weeks
  - infants with an unstable clinical course who are at high risk (as determined by the neonatologist or paediatrician)
- First examination to detect ROP should be done based on post-menstrual age and post-natal age.
- Counselling on timely screening and treatment should be given to parents/carers of infants at risk and diagnosed with retinopathy of prematurity.

## TREATMENT

- Type 1 prethreshold retinopathy of prematurity (ROP) should be treated within 48 hours of diagnosis.
- Laser photocoagulation should be considered in the treatment of zone II (except posterior zone II) ROP.
- Intravitreal anti-vascular endothelial growth (anti-VEGF) factor should be considered in zone I ROP and aggressive ROP.

## FOLLOW-UP AND REHABILITATION

- Follow-up of infants with or without retinopathy of prematurity (ROP) should be done accordingly with complete eye examination, based on staging and treatment given.
- Visual rehabilitation should be provided to all visually-impaired children.

## GUIDELINES DEVELOPMENT AND OBJECTIVES

### GUIDELINES DEVELOPMENT

The members of the DG for these CPG were from the Ministry of Health (MoH), the Ministry of Higher Education (MoHE) and private sector. There was active involvement of a multidisciplinary Review Committee during the process of the CPG development.

A systematic literature search was carried out using the following electronic databases/platforms: mainly Medline via Ovid and Cochrane databases. Refer to **Appendix 1 for Example of Search Strategy**. The inclusion criteria are all infants with risk of developing ROP and those with the established disease regardless of study design. The first search was limited to literature published over the last 18 years (2005 - 2023) since the first CPG edition. The search was based on inclusion criteria and all studies were in English. In addition, the reference lists of all retrieved literature and guidelines were searched to further identify relevant studies. Experts in the field were also contacted for studies related to the issues addressed. All searches were conducted from 8 March 2022 to 23 March 2022. The literature search was repeated for all clinical questions at the end of the CPG development process allowing any relevant papers published before 17 March 2023 to be included. Future CPG updates will consider evidence published after this cut-off date. The details of the search strategy can be obtained upon request from the CPG Secretariat.

References were also made to other guidelines on ROP as listed below:

- Royal College of Paediatrics and Child Health. UK Screening of Retinopathy of Prematurity Guideline, 2022
- Royal College of Ophthalmologist, Clinical Practice Guideline on Treating Retinopathy of Prematurity in the UK, 2022

A total of 13 main clinical questions were developed under different sections. Members of the DG were assigned individual questions within these sections. Refer to **Appendix 2 for Clinical Questions**. The DG members met 18 times throughout the development of these guidelines. All literature retrieved was appraised by at least two DG members using Critical Appraisal Skill Programme checklist, presented in evidence tables and further discussed in each DG meeting. All statements and recommendations formulated after that were agreed upon by both the DG and Review Committee (RC). Where evidence was insufficient, the recommendations were made by consensus of the DG and RC. Any differences in opinion are resolved consensually. The CPG was based largely on the findings of systematic reviews, meta-analyses and clinical trials, with local practices taken into consideration.

The literatures used in these guidelines were graded using the US/ Canadian Preventive Services Task Force Level of Evidence (2001) while the grading of recommendation was done using the principles of GRADE (refer to the preceding page). The writing of the CPG follows strictly the requirement of Appraisal of Guidelines for Research and Evaluation (AGREE II).

On completion, the draft CPG was reviewed by external reviewers. It was also posted on the MoH Malaysia official website for feedback from any interested parties. The draft was finally presented to the Technical Advisory Committee for CPG and the Health Technology Assessment (HTA) and CPG Council, MoH Malaysia, for review and approval. Details on the CPG development by MaHTAS can be obtained from **Manual on Development and Implementation of Evidence-based Clinical Practice Guidelines** published in 2015 (available at [http://www.moh.gov.my/moh/resources/CPG\\_MANUAL\\_MAHTAS.pdf?mid=634](http://www.moh.gov.my/moh/resources/CPG_MANUAL_MAHTAS.pdf?mid=634))

## **OBJECTIVES**

The objective of the CPG is to provide evidence-based recommendations on the management of ROP on the following aspects:

- a) screening and referral
- b) diagnosis
- c) treatment and follow-up

## **CLINICAL QUESTIONS**

Refer to **Appendix 2**.

## **TARGET POPULATION**

### **Inclusion Criteria**

All infants with risk of developing ROP and those with the established disease

## **TARGET GROUP/USER**

This document is intended to guide healthcare professionals and relevant stakeholders involved in the management of ROP. These include:

- i. healthcare professionals (doctors, pharmacists and allied health professionals)
- ii. medical students and trainees
- iii. policy makers
- iv. professional organisations
- v. patients, caregivers and their advocates

## **HEALTHCARE SETTINGS**

Primary, secondary and tertiary care



## DEVELOPMENT GROUP

### Chairperson

Dr. Norhafizah Hamzah  
Head of Department & Paediatric Ophthalmologist  
Hospital Tunku Azizah  
Kuala Lumpur

### Members (in alphabetical order)

Ms. Arifah Nur Yahya  
Optometrist  
Hospital Queen Elizabeth  
Sabah

Dr. Nurfahzura Mohd Jamil  
Comprehensive Ophthalmologist  
Hospital Sungai Buloh  
Selangor

Professor Dr. Choo May May  
Consultant Paediatric Ophthalmologist &  
Academic Professor  
Pusat Perubatan Universiti Malaya  
Kuala Lumpur  
Affiliated with Save Sight Institute,  
University of Sydney, Australia

Associate Professor Dr. Safinaz Mohd  
Khialdin  
Consultant Paediatric Ophthalmologist &  
Medical Lecturer  
Hospital Pakar Kanak-kanak Universiti  
Kebangsaan Malaysia, Kuala Lumpur

Dr. Farah Inaz Syed Abdullah  
Consultant Neonatologist  
Hospital Tunku Azizah  
Kuala Lumpur

Dr. Sakinah Sulong  
Family Medicine Specialist  
Klinik Kesihatan Masai  
Masai, Johor

Dr. Karen Sharmini Sandanasamy  
Public Health Physician  
Health Technology Assessment Section  
Ministry of Health, Putrajaya

Dr. Siti Norzalehawati Sepian  
Paediatric Ophthalmologist  
Hospital Sultanah Nur Zahirah  
Terengganu

Dr. Mohd. Aminuddin Mohd. Yusof  
Head of CPG Unit & Public Health Physician  
Health Technology Assessment Section  
Ministry of Health, Putrajaya

Dr. Wendy See Yen Nee  
Ophthalmologist  
Hospital Umum  
Sarawak

Dr. Nor Akmal Bahari  
Paediatric Ophthalmologist  
Hospital Kuala Lumpur  
Kuala Lumpur

Dr. Widad Md Yusof @ Mohd Yusof  
Consultant Vitreoretinal Surgeon  
Hospital Selayang  
Selangor

Dr. Norazah Abdul Rahman  
Consultant Paediatric Ophthalmologist &  
Strabismus  
Ramsay Sime Darby Medical Centre  
Selangor

## **REVIEW COMMITTEE**

The draft guidelines were reviewed by a panel of experts from both public and private sectors. They were asked to comment primarily on the comprehensiveness and accuracy of the interpretation of evidence supporting the recommendations in the guidelines.

### **Chairperson**

Dr. Jamalia Rahmat  
Senior Consultant Paediatric Ophthalmologist  
Hospital Kuala Lumpur  
Kuala Lumpur

### **Members (in alphabetical order)**

Datuk Dr. Hajjah Nor Fariza Ngah  
Head of Service &  
Senior Consultant Ophthalmologist  
Hospital Shah Alam  
Selangor

Ms. Najihah Mohamad Shukri  
Pharmacist  
Hospital Tunku Azizah  
Kuala Lumpur

Dr. Izzuna Mudla Mohamed Ghazali  
Deputy Director & Public Health Physician  
Health Technology Assessment Section  
Ministry of Health, Putrajaya

Dr. Nor Higrayati Ahmad Kasah  
Senior Consultant Ophthalmologist  
Hospital Sultanah Nur Zahirah  
Terengganu

Dr. Manoharan Shunmugam  
Consultant Ophthalmologist, Adult &  
Paediatric Vitreoretinal Surgeon  
OasisEye Specialists, Kuala Lumpur

Ms. Nor Aishah A Wahab  
Optometrist  
Hospital Kuala Lumpur  
Kuala Lumpur

Dr. Neoh Siew Hong  
Senior Consultant Neonatologist

## EXTERNAL REVIEWERS (in alphabetical order)

The following external reviewers provided feedback on the draft:

Professor Dr. Chen Ai Hong  
Professor of Optometry  
University Teknologi MARA  
Selangor

Associate Professor Dr. Saharuddin  
Ahmad  
Family Medicine Consultant  
Faculty of Medicine  
Universiti Kebangsaan Malaysia,  
Kuala Lumpur

Associate Professor Dr. Christopher Tinley  
Head of Clinical Research Unit &  
Postgraduate Program Director  
University of Cape Town, Cape Town  
South Africa

Professor Dr. Hajah Shatriah Ismail  
Head of Department &  
Consultant Paediatric Ophthalmologist &  
Strabismus  
School of Medical Sciences  
Universiti Sains Malaysia, Kelantan

Professor Dr. Frank Martin  
Consultant Paediatric Ophthalmologist  
Sydney Eye Hospital, University of Sydney  
Sydney, Australia

Dr. Siti Hazury Zaulkifli  
General Practitioner  
Canon In-House Clinic  
Canon Opto (M) Sdn. Bhd.  
Shah Alam, Selangor

Dr. Jafanita Jamaludin  
Senior Principal Assistant Director  
& Head of O&G & Paediatric Services Unit  
Medical Services Development Section  
Ministry of Health, Putrajaya

Associate Professor Dr. Shuaibah Ab  
Ghani  
Lecturer & Consultant Paediatric  
Ophthalmologist & Strabismus  
Universiti Malaysia Sabah, Sabah

Ms. Lynne Speedwell  
Head of Optometry  
Clinical & Academic Department of  
Ophthalmology  
Great Ormond Street Hospital for Children  
NHS Foundation Trust  
London, United Kingdom

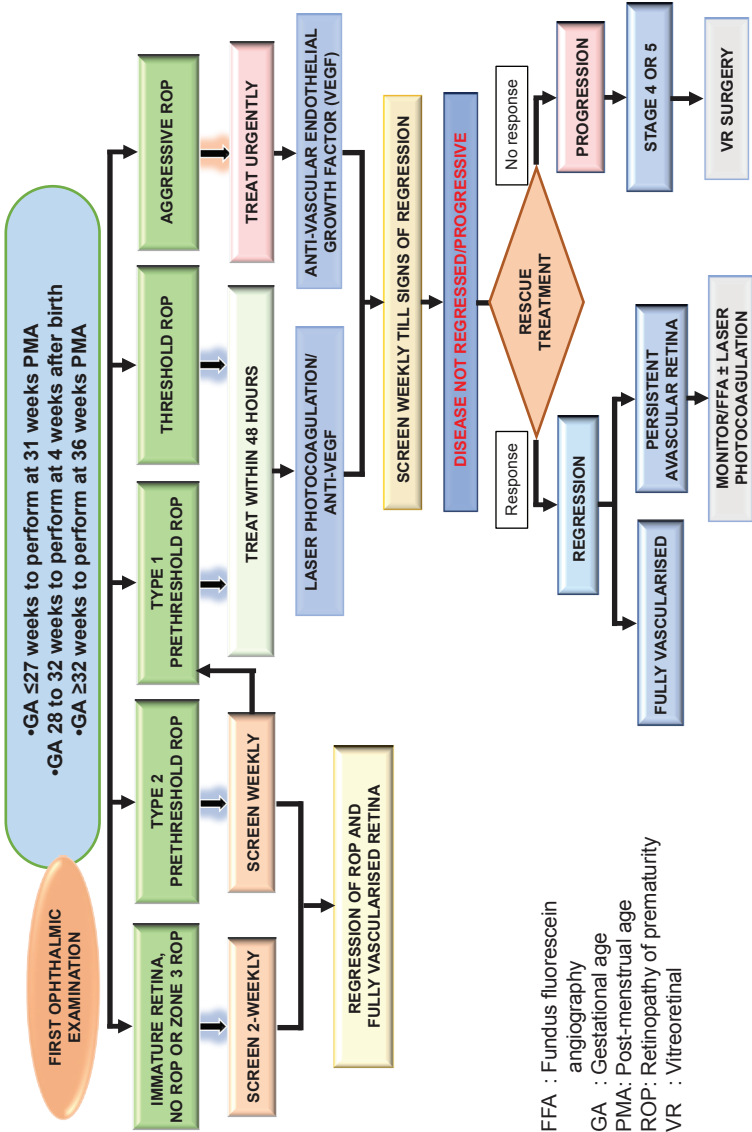
Ms. Tiffany Savitri  
Patient Advocate

Dr. Norshireen Nazli Abdul Razak  
Consultant Paediatrician  
Hospital Tunku Azizah  
Kuala Lumpur

Dr. Zainora Mohammed  
Senior Lecturer  
Program of Optometry & Vision Science  
Faculty of Health Science  
Universiti Kebangsaan Malaysia  
Kuala Lumpur

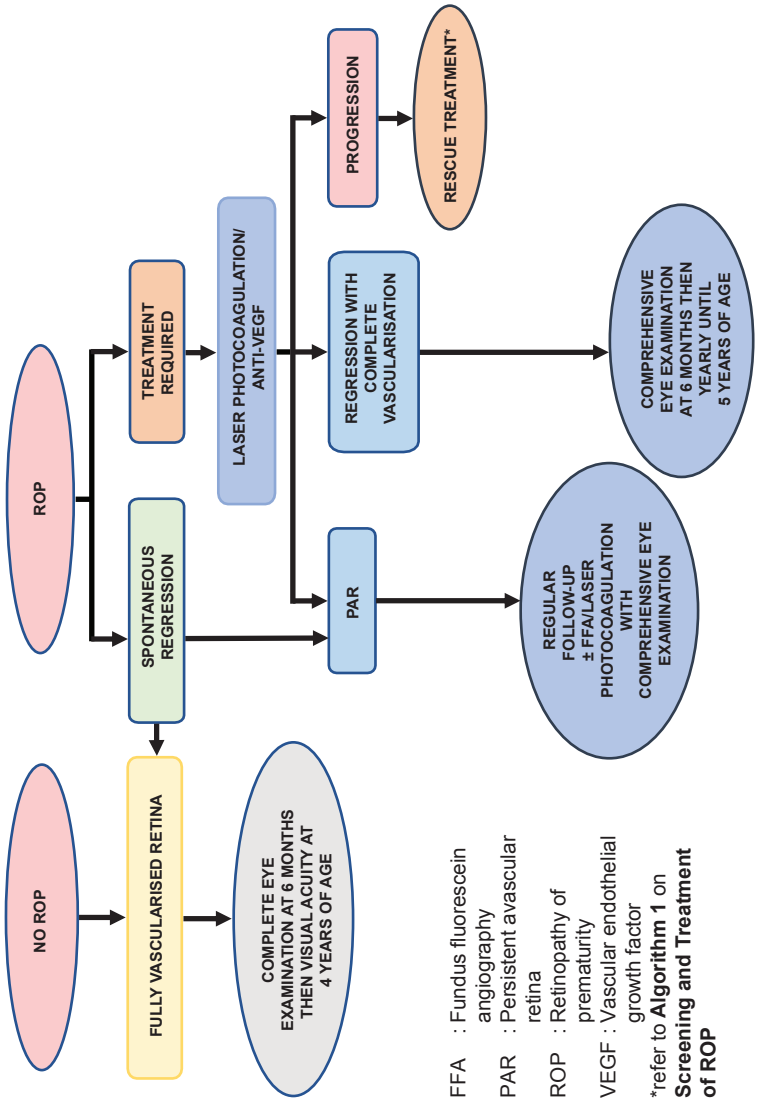
Professor Dr. Nurliza Khaliddin  
Consultant Paediatric Ophthalmologist  
Department of Ophthalmology  
Faculty of Medicine  
University of Malaya  
Kuala Lumpur

**ALGORITHM 1. SCREENING AND TREATMENT OF RETINOPATHY OF PREMATURITY**



FFA : Fundus fluorescein angiography  
 GA : Gestational age  
 PMA: Post-menstrual age  
 ROP: Retinopathy of prematurity  
 VR : Vitreoretinal

**ALGORITHM 2. FOLLOW-UP OF RETINOPATHY OF PREMATURITY**



FFA : Fundus fluorescein angiography  
 PAR : Persistent avascular retina  
 ROP : Retinopathy of prematurity  
 VEGF : Vascular endothelial growth factor  
 \*refer to **Algorithm 1 on Screening and Treatment of ROP**

## 1. INTRODUCTION

Retinopathy of prematurity (ROP) is a vasoproliferative disease in the developing retinal vessels of premature infants. This potentially blinding condition is largely preventable if appropriate, adequate and accessible screening programme are available. However, the pre-existing ROP screening protocol needs to be updated based on the latest development in neonatal care.

A 2019 report by the Malaysian National Neonatal Registry reviewed the screening for ROP of 2,145 inborn infants at gestational age <32 weeks who survived to six weeks of age before discharged from neonatal care. A total of 87.1% infants did not have ROP, 10.7% had ROP stage 1 or 2, 1.6% stage 3 and 0.4% stage 4 or 5. The incidence rate of severe ROP (stage 3, 4 and 5) were 20%, 7% and 0.7% in infants with gestational age of 22 - 24 weeks, 25 - 27 weeks and 28 - 31 weeks respectively. A total of 38 infants had laser therapy and one infant underwent cryotherapy.<sup>1, level III</sup>

The first local edition of the clinical practice guidelines (CPG) on the management of ROP was published in 2005. With the advances in research and technology, there is a great shift in the paradigm of classification and treatment of the disease. This current edition intends to update the recommendations in the management which includes International Classification of Retinopathy of Prematurity Third Edition (ICROP-3) classification, intravitreal anti-vascular endothelial growth factor (anti-VEGF) treatment and vitrectomy techniques.

It is hoped that this latest edition of the CPG will improve the management of ROP and thus prevent visual impairment (VI) and blindness in the affected children.



## 2. RISK FACTORS

There are various systemic risk factors that influence the development and progression of ROP. Among these, low gestational age (GA) and low birth weight (BW) are the strongest and most established risk factors.

### a. Prematurity

Gestational age is the most predictive risk factor for the development of ROP.<sup>2</sup>

### b. Low birth weight

The incidence of ROP was 68% among infants weighing <1251 g.<sup>3, level I</sup>

### c. Small for gestational age

Intrauterine growth restriction is significantly associated with development of Aggressive ROP (AROP).<sup>4, level II-2</sup>

In a meta-analysis of 20 cohort studies, small for gestational age (SGA) in preterm infants was associated with severe ROP (OR=1.92, 95% CI 1.57 to 2.34) and treated ROP (OR=1.39, 95% CI 1.18 to 1.65). Based on Newcastle-Ottawa Scale (NOS), 14 studies had low risk of bias and seven studies had moderate risk.<sup>5, level I</sup>

### d. Supplemental oxygen

In a secondary analysis of the Surfactant Positive Airway Pressure and Pulse Oximetry Trial (SUPPORT) trial on survived premature infants of 24 - 27 weeks' gestational age, total duration of supplemental oxygen (SpO<sub>2</sub> of 91% - 96%) between two and five weeks was associated with risk of severe ROP and this showed a dose-response relationship.<sup>6, level I</sup>

A meta-analysis of five randomised controlled trials (RCTs) looked into the effect of targeting a lower oxygen saturation range in extremely preterm infants from birth or soon after. Although the lower SpO<sub>2</sub> target group had a lower risk of treatment for ROP (RR=0.74, 95% CI 0.63 to 0.86) than higher SpO<sub>2</sub> target group, it had a higher risk of death (RR=1.17, 95% CI 1.04 to 1.31). Using Cochrane Risk of Bias, the trials were assessed as being at low risk of bias for all domains.<sup>7, level I</sup> These findings were supported by an earlier Cochrane systematic review on the same five RCTs but based on an analysis using aggregated data.<sup>7, level I</sup>

### e. Blood transfusion

In another meta-analysis, 13 cohort studies on preterm infants with a GA of ≤32 weeks showed that red blood cell transfusion was an independent risk factor for the development of ROP (OR=1.77, 95%

CI 1.29 to 2.43). However, there was no evidence to support its effect of red blood cell transfusion on ROP in the older GA groups. The Newcastle-Ottawa Scale (NOS) score of the included studies ranged from 6 to 8,<sup>8, level I</sup>

#### **f. Sepsis**

A meta-analysis of 16 studies demonstrated that sepsis being strongly associated with severe ROP (OR=2.33, 95% CI 1.21 to 4.51). However, the primary studies had high heterogeneity and were rated as low in quality.<sup>9, level I</sup>

Chorioamnionitis was significantly associated with development of AROP.<sup>4, level II-2</sup>

#### **g. Necrotising enterocolitis**

A multicentre cohort study determined the association of surgical necrotising enterocolitis (NEC) and its timing with the development of ROP. The findings supported the association of ROP with NEC:<sup>10, level II-2</sup>

- infants with surgical NEC had higher risk of any ROP and severe ROP than those without [OR of 2.7 (95% CI 1.9 to 3.7) and 2.5 (95% CI 1.9 to 3.3) respectively]
- subgroup analysis showed that infants with early surgical NEC were at higher ROP risk than late surgical NEC

There was no significant difference in co-morbidities [chronic lung disease, severe intraventricular haemorrhage (Grades III or IV), hydrocephalus, patent ductus arteriosus and periventricular leukomalacia] between the early and late surgical NEC groups.

### 3. IDENTIFICATION AND SCREENING OF INFANTS AT RISK

#### 3.1 Screening Criteria

Screening for ROP has been recommended to be carried out for infants with either:<sup>2</sup>

- BW <1500 g
- GA <32 weeks
- infants with an unstable clinical course who are at high risk (as determined by the neonatologist or paediatrician)

In the United Kingdom (UK), the screening criteria for ROP is GA <31 weeks (up to and including 30 weeks and six days) and/or BW <1501 g<sup>11</sup> whereas in the United States of America (USA), the criteria is set at GA ≤30 weeks and/or BW ≤1500 g.<sup>12</sup>

In a systematic review of 18 studies on screening for ROP in premature infants, the risk of ROP was 30.7% in those born at GA ≤30 weeks or BW ≤1500 g. The risk increased to 62.9% among those who were ≤27 weeks of GA and/or ≤750 g BW. The odds of developing ROP was 1.4 times for every week decrease in GA and 1.8 times for every 100 g decrease in BW.<sup>13, level II-2</sup>

In a cross-sectional study on severe ROP, 13% of infants in moderate/low developed countries had BW and GA exceeding the UK screening criteria.<sup>14, level III</sup>

A prospective study using USA and UK screening criteria for ROP in more mature and larger premature infants, the findings were:<sup>15, level III</sup>

- premature infants with BW >1500 g had 34.6% ROP and 25.9% of them required treatment
- 25.8% of premature infants with GA >32 weeks had ROP and 10.8% of them needed treatment
- 14.7% treatment-requiring ROP would have been missed based on the USA screening criteria
- 9.4% with severe ROP would have been missed based on the UK screening criteria

Based on the evidence discussed above, the CPG DG has decided to revise the screening criteria using the BW <1750 g and GA <34 weeks.

#### **Recommendation 1**

- Screening for retinopathy of prematurity should be done for infants with either one of the following criteria:
  - birth weight <1750 g
  - gestational age <34 weeks
  - infants with an unstable clinical course who are at high risk (as determined by the neonatologist or paediatrician)

Timing to screen ROP is important as well. As ROP takes the longest to develop in the most immature infants, too early a screening may not detect any abnormalities. If it is done late, there is a risk of development of poor outcomes due to late detection of prethreshold ROP that require treatment.

In a five years retrospective cohort study on the optimisation of screening guidelines on ROP in premature infants, the findings were:<sup>16, level II-2</sup>

- a. median postnatal age (PNA) at developing ROP was inversely associated with GA at birth for premature infants i.e. -
  - for GA <25 weeks, PNA was 8.57 weeks (range of 6.00 - 11.71)
  - for GA between 25 to 34 weeks, PNA were between 4.29 and 7.71 weeks
  - for GA >34 weeks, PNA was 4.71 weeks (range of 1.71 - 11.43)
- b. no infant developed Type 1 ROP or other ROP needing treatment:
  - before reaching a post-menstrual age (PMA) <32 weeks regardless of GA
  - before reaching a PNA of four weeks for premature infant with a GA of <32 weeks

Timing of the initial examination is based on both PMA and PNA where 99% of infants at risk of a poor visual outcome can be detected. The recommended optimum timing for first screening is shown in **Appendix 3**.

### **Recommendation 2**

- First examination to detect retinopathy of prematurity should be done based on post-menstrual age and post-natal age.

## **3.2 Counselling**

Counselling is an important component in the management of ROP. It has to be done in a safe, timely and coordinated manner to prevent delays in management and alleviate uncertainties in parents'/carers' mind. These can help them in the overall care of their infants including regular check-ups through positive communications with the healthcare providers.<sup>17, level III</sup>

There are a few aspects to be considered when delivering the counselling to parents/carers of the infants. They are:

- **Who need to be screened?**  
Infants delivered <34 weeks of gestation or BW <1750 g
- **Why screening and treatment is needed?**  
ROP can cause blindness and permanent damage to the retina if timely screening and treatment is not carried out.

- **What are the available options for treatment?**  
Laser photocoagulation for severe ROP (stage 3 and above). Anti-VEGF injection can also be offered in some severe ROP.
- **What are the adverse events (AEs) of treatment?**  
Infant's eye may look red and swollen. Low incidence of eye infection, cataract and life-long risk of retinal detachment (RD) have been reported.
- **What are the monitoring criteria for treated infants?**  
Infants are reviewed between two days to a week after treatment. Up to 10% of treated infants may require retreatment.

Counselling should be given prior to screening and initiation of treatment.<sup>18</sup>

- The counselling on screening can be given by paediatric doctors and Neonatal Intensive Care Unit (NICU) nurses while counselling on treatment is only to be delivered by the treating ophthalmologists.

### **Recommendation 3**

- Counselling on timely screening and treatment should be given to parents/carers of infants at risk and diagnosed with retinopathy of prematurity.

## **3.3 Preparation for Screening**

For effective screening purposes, the eyes need to be fully dilated. In local clinical practice, the infants are usually kept fasted from the time of dilatation. Excess drops are needed to be wiped off to reduce systemic absorption and side effects.

### **a. Dilating regime**

A systematic review showed that heterogeneous combinations of mydriatic eye drops (cyclopentolate, tropicamide and phenylephrine) were generally effective and safe to be used for ROP examination. The lowest concentration regimen to provide adequate dilatation was a combination of phenylephrine 1% and cyclopentolate 0.2% (one drop each). Systemic absorption of mydriatics had been associated with clinically significant and sometimes life-threatening cardiovascular, respiratory and gastrointestinal AEs.<sup>19, level I</sup> The quality of the primary papers was low to moderate.

- Combination of Gutt cyclopentolate 0.2% and Gutt phenylephrine 1% (e.g. Gutt cyclomydril) may be used as the preferred dilating regime.
- Monitoring for AEs are strongly advised in the use of mydriatic eye drops.

Alternative dilating regimes and their pharmacokinetics and pharmacodynamics are shown in **Appendix 4**.

### **b. Pain relief**

A meta-analysis of four RCTs found that sucrose was significantly more effective than placebo to reduce pain during ROP examination in preterm infants. The concentration of sucrose used in these studies ranged at 24% to 33%. However, there may be a combined effect of topical anaesthesia as it was used in three of the RCTs. Apart from that, topical anaesthetic eye drops alone showed mixed results in reducing pain while non-pharmacological interventions e.g. swaddling, sucking and adjusting the environment (dim lighting with reduced sound and activity level) did not significantly reduced pain. Overall, the quality of the studies included was good.<sup>20, level I</sup>

A large RCT demonstrated that 1 ml of oral sucrose 25% given for two minutes along with topical anaesthesia before ROP examination significantly reduced clinically-observed pain based on Neonatal Infant Pain Scale.<sup>21, level I</sup>

- Oral sucrose should be considered to be used with topical anaesthesia in retinopathy of prematurity examination.

## **3.4 Screening Methods**

### **a. Conventional gold standard**

The conventional screening methods for ROP is performed by the ophthalmologist using a gold standard which is the Binocular Indirect Ophthalmoscopy (BIO) in fully dilated eyes. Through technological evolution, new screening methods using imaging techniques have been introduced e.g. digital retinal photography and smart phone-assisted imaging techniques.

### **b. Digital retinal photography**

In a systematic review, ROP screening by non-ophthalmologists using digital retinal photography was shown to be a potentially useful tool to diagnose treatment-warranted ROP (TW-ROP) or referral-warranted ROP compared with BIO.<sup>22, level II-2</sup>



A diagnostic study supported the use of wide-field digital retinal imaging in the diagnosis of severe and TW-ROP with 100% sensitivity and specificity. However, BIO remained superior in detection of mild ROP in the peripheral fundus.<sup>23, level III</sup>

In a cross-sectional study, wide-field digital retinal photography by neonatal nurses was effective for diagnosing referral-warranting ROP with a sensitivity of 80% and specificity of 94.5%.<sup>24, level III</sup>

### c. Telemedicine

A multicentre diagnostic study showed that remote interpretation of digital fundus images was a useful adjunct for ROP screening with BIO as a reference standard. The sensitivities were high at 92% for both clinically significant ROP and prethreshold Type I ROP.<sup>25, level III</sup>

The Stanford University Network for Diagnosis of ROP (SUNDRROP) study on 6-year telemedicine initiative reported high diagnostic accuracy of retinal images done by trained nurses remotely and interpreted by a ROP specialist in a centre. All images were compared with the gold standard of BIO results by a paediatric retinal specialist. The sensitivity was 100%, specificity 99.8%, positive predictive value (PPV) 95.5% and negative predictive value (NPV) 100% for the detection of TW-ROP. There were no adverse anatomical outcomes observed.<sup>26, level III</sup>

On the other hand, the Karnataka Internet Assisted Diagnosis of ROP (KIDROP) tele-ROP model required trained technicians to identify patients with TW-ROP and send images to the ROP expert for verification. Once ROP were confirmed, the patient underwent BIO before treatment was instituted. The sensitivity, specificity, PPV and NPV of image grading by the technician were 95.7% (95% CI 85.1 to 99.3), 93.2% (95% CI 87.7 to 96.7), 81.5% (95% CI 68.6 to 90.7) and 98.6% (95% CI 94.9 to 99.8) respectively.<sup>27, level III</sup>

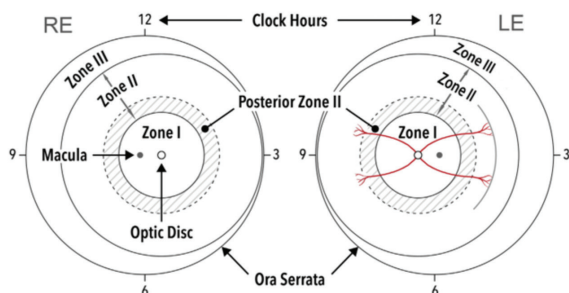
### Recommendation 5

- Binocular indirect ophthalmoscopy (BIO) should be used for screening retinopathy of prematurity (ROP) and performed by the ophthalmologist.
- Wide-field retinal imaging should be considered to detect treatment-warranted or referral-warranted ROP.
  - This may be done by non-ophthalmologists with remote interpretation via telemedicine.
  - The findings should be confirmed by BIO prior to treatment.

#### 4. CLASSIFICATION

The ICROP-3 has been published in 2021. It retains current definitions e.g. zone (location of disease), stage (appearance of disease at the avascular and vascular junction) and circumferential extent of disease. The major updates include:<sup>28, level III</sup>

- refined classification metrics (e.g. posterior zone II, notch, subcategorisation of stage 5 and recognition of continuous spectrum of plus disease)
- definition of AROP replacing aggressive-posterior ROP (APROP) because of increasing recognition that aggressive disease may occur in larger preterm infants and beyond the posterior retina



**Figure 1: Updates of Retinal Zones for ROP**

**Source:** Chiang MF, Quinn GE, Fielder AR, et al. International Classification of Retinopathy of Prematurity, Third Edition. *Ophthalmology*. 2021;128(10):e51-e68

**Figure 1** illustrates the updates of the retinal zones in ICROP-3 which shows schema of right eye (RE) and left eye (LE) zone borders and clock hour sectors. It describes the location of vascularisation and extent of retinopathy. Refer to:

- **Appendix 5** on Summary of Key Components of International Classification of Retinopathy of Prematurity Third Edition
- **Appendix 6** for visual illustration of ROP

## 5. NATURAL COURSE OF DISEASE

There are a few landmark studies on ROP. One of them is the Early Treatment for ROP (ETROP), a large multicentre RCT which was published in 2005. It recruited infants with BWs <1,251 g and at high-risk bilateral prethreshold ROP. The study population had one eye randomised to early retinal ablative treatment (laser photocoagulation or cryotherapy) and the fellow eye managed conventionally (control eye).<sup>29, level I</sup> A few publications were produced from this main study.

A study, part of ETROP, addressed on the natural progression of Type 2 to Type 1 ROP. A total of 22% Type 2 ROP cases progressed to Type 1 with a mean interval of 9.0±6.6 day while 11.5% progressed in less than seven days. In the latter, the risk of progression was greatest between 33- and 36-weeks' PMA regardless of zone of retinopathy. It was shown that Type 1 ROP can be identified with weekly examinations in most eyes with an initial diagnosis of Type 2 ROP.<sup>30, level I</sup>

In a national population-based study on preterm infants born before 27 weeks' gestation, the natural history of ROP was analysed and showed:<sup>31, level II-2</sup>

- a total of 72.7% of infants developed ROP
  - symmetrical stages of ROP in both eyes were at 83.8% and the correlation for the maximal stage of ROP was significant
  - ROP was first localised temporally in 48.7% eyes, nasal retina in 27.6% eyes and, both temporally and nasally in 23.7% eyes
  - nasal onset was significantly associated with severe ROP, even after adjusting for gestational age at birth
  - time from onset of ROP to stage 3 was shorter in infants who met criteria for treatment\* compared with those who did not (median 14 vs 20.5 days; p<0.05)
- \*refer to **Appendix 7**.

In a cross-sectional study on the clinical features of untreated ROP with spontaneous regression, the following were noted:<sup>32, level III</sup>

- onset of regression was at a median of 40 weeks PMA for acute ROP and completely regressed by a median of 49 weeks of PMA
- average duration for regression was 8.5 weeks
- zone II ROP and stage 3 ROP had a longer duration of regression with a later time for onset and completion of regression
- anaemia and retinal haemorrhage were independent risk factors for delayed regression
- among the abnormalities seen in spontaneously regressed ROP were avascular retina in temporal periphery (19.0%), increased vascular branching (6.8%), retinal pigmentary changes (6.8%) and, smaller angle between upper and lower temporal retinal vessel trunks (3.0%)

In another cross-sectional study of acute ROP not requiring treatment, the natural involution (regression) and risk factors of delayed involution were identified:<sup>33, level III</sup>

- involution began at a mean of 40.4 weeks PMA and completed at a mean of 50.6 weeks PMA with an earlier completion seen in zone III compared with zone II ( $p < 0.01$ )
- mildest disease (stage 1 at 38.1 weeks PMA) involuted earlier and latest with most serious disease (stage 3 at 42.3 weeks PMA) ( $p < 0.01$ )
- time taken to complete involution was longer in zone II than zone III ( $16.04 \pm 12.35$  weeks vs  $8.30 \pm 7.3$  weeks) and stage 3 than stage 1 and stage 2 disease ( $23.88 \pm 10.58$  weeks,  $2.03 \pm 0.96$  weeks and  $7.69 \pm 4.75$  weeks respectively;  $p < 0.01$ )
- significant risk factors for delayed involution were continuous positive airway pressure (CPAP), active stage 3 disease and anaemia

- Nasal onset is significantly associated with severe ROP.
- Risk of ROP progression is greatest between 33 and 36 weeks of PMA.
- In Type 2 ROP, weekly follow-up may identify progression to Type 1 ROP.
- Regression of ROP occurs between 40 and 50 weeks of PMA.

## 6. TREATMENT

The principle of treatment in ROP is to remove the stimulus for growth of abnormal blood vessels. For acute proliferative phase, the treatment is targeted to decrease angiogenic activity of VEGF. It can be attained through ablation of the peripheral avascular retina by laser photocoagulation and intravitreal anti-VEGF. This will in turn reduce the incidence of RD and consequent blindness.

### 6.1 Indication of Treatment

Indication of treatment for Type 1 ROP according to the ETROP study:<sup>3, level I</sup>

- zone I ROP: any stage with plus disease
- zone I ROP: stage 3 without plus disease
- zone II ROP: stage 2 or 3 with plus disease

Refer to **Appendix 7** on features of ROP that require treatment.

### 6.2 Optimum Timing for Treatment

The ETROP study on infants with Type 1 prethreshold ROP and treated within 48 hours showed:<sup>3, level I</sup>

- significant improvement in visual acuity (VA) outcomes and structural outcomes at nine months of PMA
- support for retinal ablative therapy for Type 1 ROP and a wait-and-watch (minimum of 2-weekly) approach to Type 2 ROP

The clinical guidelines on treating ROP in UK recommends the following:<sup>34</sup>

- Infants with AROP or zone I stage 3 with plus ROP should be treated as soon as possible and within 48 hours.
- Infants with zone I stage 1 or 2 ROP with plus disease, zone I stage 3 ROP without plus disease zone II stage 2 or 3 with plus disease should be treated within 48 - 72 hours.

- The CPG RC and DG opine that weekly examination is required for monitoring Type 2 prethreshold ROP.

#### Recommendation 6

- Type 1 prethreshold retinopathy of prematurity should be treated within 48 hours\* of diagnosis.

\*subject to infant's stability

## 6.3 Options of Treatment

Treatment options for ROP can be divided into pharmacotherapies, ablative therapies and surgical interventions.

### 6.3.1 Laser photocoagulation

ROP can be treated with laser photocoagulation which targets the avascular retina. The laser application aims to reduce the high levels of VEGF produced in ROP and inhibit neovascularisation. The effectiveness and safety of transpupillary diode and argon laser are discussed below.

The landmark study of ETROP supported significantly the use of laser photocoagulation in the reduction of unfavourable VA outcomes from 19.8% to 14.3% and structural outcomes from 15.6% to 9.0% at 6 and 9 months corrected age.<sup>3, level I</sup>

A non-randomised clinical trial comparing the effectiveness and safety between transscleral and transpupillary diode laser photocoagulation found no significant difference in the rate of regression of new vessel and plus, refractive error, axial length and unfavourable structural outcome (macular dragging and progression to stage 4 and 5). However, transscleral laser generated larger areas of scarring and 2.8% of vitreal haemorrhage.<sup>35, level II-1</sup>

In a cohort study on the effectiveness and safety of diode laser photocoagulation, the findings were:<sup>36, level II-2</sup>

- a significant reduction in the plasma VEGF-A, vascular endothelial growth factor receptor-2 and endothelium-specific receptor tyrosine kinase levels at one day and one week after laser photocoagulation with resolution of active retinopathy within a week and no recurrence within a year
- AE reported were bradycardia and/or oxygen desaturation along with minor preretinal bleeding during the treatment

Two follow-up studies from the ETROP study looked into the AEs occurring after laser photocoagulation and cryotherapy. In the first study of six years follow-up, the incidence of glaucoma was 1.67% and this was noted in the first five years. All affected patients had poor visual outcomes. Glaucoma in ROP is often described as a narrow angle with a shallow anterior chamber associated with a retrolental membrane pushing the iris-lens diaphragm forward or a swollen lens.<sup>37, level I</sup> However, the intraocular pressure measurement is not routinely performed.

The second study reported the incidence of cataract of 1.9% at 6 months follow-up regardless of laser treatment status. Among the



possible causes proposed for cataract formation were lens changes due to heat transferred from laser energy being absorbed by vessels on the lens capsule and anterior segment ischaemia.<sup>38, level I</sup>

The clinical guidelines on treating ROP in UK recommends:<sup>34</sup>

- treatment-requiring ROP in zone II (except posterior zone II) should be treated with laser photocoagulation
- the first examination post-laser photocoagulation should take place 5 - 9 days after treatment and continue weekly till regression occurs
- from 7 - 14 days, re-treatment with laser should be considered if disease regression is inadequate and untreated retinal areas are identified
- rescue treatment with an anti-VEGF agent should be considered from 14 days if regression is inadequate despite optimal laser treatment being delivered

#### **Recommendation 7**

- Laser photocoagulation should be considered in the treatment of zone II (except posterior zone II) retinopathy of prematurity.

Refer to **Appendix 8 for Laser Photocoagulation in ROP.**

#### **6.3.2 Intravitreal anti-vascular endothelial growth factor**

Anti-VEGF agents have been used as therapeutic agents for zone 1 ROP and AROP due to their ability to impede pathologic neovascularisation. Currently, the available drugs in Malaysia that inhibit VEGF are bevacizumab, ranibizumab and aflibercept. In MoH, ranibizumab is the only anti-VEGF authorised to be used for ROP. There were four meta-analyses comparing intravitreal anti-VEGF and laser photocoagulation in ROP. They found no difference in treatment outcomes and three studies showed reduction in risk of myopia in the anti-VEGF treated group. The details are described below.

In the first meta-analysis of ten clinical trials on Type 1 and threshold ROP, anti-VEGF had higher retreatment incidence compared with laser photocoagulation (OR=2.52, 95% CI 1.37 to 4.66). However, there were no significant differences in terms of time between treatment and retreatment, recurrence and eye complications (e.g. corneal opacity, cataract, preretinal or intravitreal haemorrhage and RD). On the other hand, Spherical Equivalent (SE) (degree of myopia) was higher in laser photocoagulation (WMD=3.03 D, 95% CI 1.48 to 4.59). The quality of the primary papers in the meta-analysis was moderate.<sup>39, level I</sup>

In a later meta-analysis of seven RCTs on ROP, there were no significant differences between anti-VEGF monotherapy (e.g. bevacizumab,

ranibizumab, aflibercept and pegaptanib) and laser photocoagulation in the rates of recurrence, treatment switching, retreatment and mortality. However, there was less AEs (myopic changes and unfavourable structural outcomes e.g. macular ectopia, retinal folds, vitreous and retinal haemorrhages, and RD) in anti-VEGF (RR=0.17, 95% CI 0.07 to 0.44). GRADE showed low to high quality assessment of the outcomes in the RCTs.<sup>40, level I</sup>

A Cochrane systematic review revealed no differences between anti-VEGF (bevacizumab/ranibizumab) monotherapy and laser photocoagulation in preterm infants with Type 1 pretreshold ROP in the following outcomes:<sup>41, level I</sup>

- risk of complete or partial RD
- mortality before discharge
- lens opacity requiring cataract removal
- risk of recurrence of ROP requiring retreatment

GRADE showed very low to low quality assessment of the outcomes in the trials.

In the fourth meta-analysis, refractive error development in preterm children with severe ROP treated with anti-VEGF agents and laser photocoagulation was investigated. A total of two RCTs showed that the use of intravitreal bevacizumab was associated with less occurrence of refractive errors based on the following outcomes:<sup>42, level I</sup>

- SE with mean difference (MD) of 4.65 (95% CI 2.02 to 7.29)
- prevalence of high myopia with RR of 0.22 (95% CI 0.06 to 0.88)

The risk of bias in both RCTs was reported as low and high.

A multicentre cohort study analysed infants with ROP treated with bevacizumab or laser photocoagulation. The findings showed no association of ROP treatment modality in death or severe neurodevelopmental impairment. The higher mortality and poor cognitive outcomes in early childhood for bevacizumab group were due to lower BW, prolonged duration of conventional ventilation and supplemental oxygen.<sup>43, level II-2</sup>

The ranibizumab vs laser therapy for the treatment of very low birthweight infants with ROP (RAINBOW) core trial compared the effectiveness and safety of intravitreal ranibizumab (0.2 mg and 0.1 mg) with laser photocoagulation for very low birthweight infants (<1500 g) with ROP found:<sup>44, level I</sup>

- both 0.2 and 0.1 mg ranibizumab had greater treatment success although non-significant [OR of 2.19 (95% CI 0.99 to 4.82) and 1.57 (95% CI 0.76 to 3.26) respectively]; treatment success was defined by survival without active ROP, unfavourable structural outcomes or the need for a treatment modality other than that

assigned (treatment switch) in both eyes up to 24 weeks after starting investigational treatment

- both systemic and ocular AEs were similarly distributed between the three intervention groups

In an extension study of two years of RAINBOW trial, the following outcomes were documented:<sup>45, level I</sup>

- rate of structural abnormalities ranged from 2 to 9% in the study subjects; however, there was no significant difference in risk between ranibizumab 0.2 mg, ranibizumab 0.1 mg and laser photocoagulation groups
- prevalence of high myopia per eye was lower in the 0.2 mg ranibizumab group than in the laser photocoagulation group (OR= 0.19,95% CI 0.05 to 0.69) but there was no significant difference between ranibizumab 0.1 mg and laser or ranibizumab 0.2 mg and 0.1 mg groups
- no significant difference in composite vision-related quality of life scores between ranibizumab 0.2 mg, ranibizumab 0.1 mg and laser photocoagulation groups
- similar proportion of infants with neuro-development and growth between the three groups
- no AEs related to the study intervention

In post anti-VEGF, clinical guidelines on treating ROP in UK recommends the first examinations should take place 1 - 2 days and 5 - 7 days after treatment to detect adverse effects of treatment. Regular examinations must be maintained to detect disease reactivation: weekly for 4 weeks, 2-weekly for a further 12 weeks and then 4-weekly for a further 8 weeks (total of 24 weeks) and up to 32 weeks in eyes treated for A-ROP with bevacizumab after treatment. Disease reactivation in the form of plus disease and / or extraretinal new vessels should be treated with transpupillary laser, to produce near-confluent ablation of the entire avascular retina.<sup>34</sup>

Artificial intelligence based on vascular severity score (VSS) has been shown to detect disease regression and reactivation of ROP after anti-VEGF. This tool can be potentially used in the monitoring of ROP after treatment.<sup>46, level I</sup>

In the clinical guidelines on treating ROP in UK, treatment-requiring ROP in zone I should be treated with an intravitreal injection of an anti-VEGF agent.<sup>34</sup>

- Anti-VEGF treatment should be avoided when any signs of fibrosis is present.

**Recommendation 8**

- Intravitreal anti-vascular endothelial growth factor (anti-VEGF) should be considered in the treatment of retinopathy of prematurity (ROP).
  - Zone I ROP should be treated with an anti-VEGF agent.

The CPG DG opines that intravitreal anti-VEGF should be administered by paediatric ophthalmologist/retinal specialist/ophthalmologist who have been privileged by their healthcare facility. Refer to **Appendix 9** on Types and Properties of Anti-Vascular Endothelium Growth Factor and **Appendix 10** for **Procedure for Intravitreal Anti-VEGF Injection**.

**6.3.3 Cryotherapy**

In the extension (15 years) cryotherapy for ROP (CRYO-ROP) study on threshold ROP treated with cryotherapy, the visual and structural outcomes were:<sup>47, level I</sup>

- unfavourable VA (20/200 or worse) outcomes were found in 44.7% of treated eyes and 64.3% of control eyes ( $p < 0.001$ )
- unfavourable structural outcomes structural outcomes e.g. RDs were found in 30% of treated eyes and 51.9% of control eyes ( $p < 0.001$ )
- new RDs developed at age 10 years even in eyes with relatively good structural findings, suggesting value in long-term, regular follow-up of eyes with threshold ROP
- among the group of eyes with favourable outcomes between 10-year and 15-year examinations, there were 4.5% treated eyes and 7.7% control eyes that developed a retinal fold, RD or the posterior pole was obscured by an ROP-related abnormality (band keratopathy and moderate corneal stromal opacity, with posterior vitreous abnormalities on ultrasonography and all fundus view obstructed)

- Cryotherapy causes unfavourable structural and functional outcomes which rendered it not to be recommended in the treatment of ROP.

**6.3.4 Vitreoretinal surgery**

Effective screening and prompt treatment of acute ROP is important to minimise the number of infants that require vitrectomy surgery. Vitrectomy has been shown to show some effectiveness and safety in the treatment of ROP. These are mainly based on four case series. All showed the treatment was effective in ROP with anatomical success ranging between 61.7% and 100% in stage 4 and less in stage 5. Less than 10% of those who had vitrectomy for stage 4 ROP progressed to stage 5. Complications reported were glaucoma, vitreous haemorrhage, etc.<sup>48-51, level III</sup>

In one case series, factors significantly associated with favourable anatomical outcomes were stage 4, prior treatment (laser photocoagulation ± anti-VEGF), surgery with 25G in comparison with 23G micro incision vitrectomy surgery (MIVS) and lens sparing vitrectomy (LSV). On the other hand, retinal break was significantly associated with poor anatomical outcomes.<sup>49, level III</sup>

There was low level of evidence on scleral buckling in ROP. In a small case series of ROP stage 4, scleral buckling achieved:<sup>50, level III</sup>

- 100% anatomical success in stage 4A and 50% in stage 4B
- 50% favourable visual outcome in stage 4A and 12.5% in stage 4B

In another case series of ROP stage 4A, scleral buckling combined with anti-VEGF achieved 44.4% retinal reattachment while 55.6% required subsequent vitrectomy.<sup>51, level III</sup>

- As soon as peripheral retinal traction has been detected, the infant should be referred for early vitreoretinal surgery.

### 6.3.5 Adjunctive treatment

In a Cochrane systematic review of three RCTs on the use of topical and systemic beta-blockers for prevention and treatment of ROP in preterm infants, the findings were:<sup>52, level I</sup>

- beta-blockers prevented rescue treatment with anti-VEGF agents by 68% (RR=0.32, 95% CI 0.12 to 0.86)
- beta-blockers prevented treatment with laser photocoagulation or cryotherapy by 46% (RR=0.54, 95% CI 0.32 to 0.89)
- beta-blockers prevented progression to stage 2 ROP with plus disease, stage 3 to 5 but only progression to stage 3 was significant (RR=0.60, 95% CI 0.37 to 0.96)
- AEs reported by one RCT were hypotension, bradycardia, bronchospasm and apnoea but they were not significant

Based on the GRADE assessment, the primary papers were of moderate to low quality.

- Beta-blockers have been shown to be an effective and safe new adjunctive treatment in ROP. AEs should be monitored in its use.

In a systematic review of nine RCTs, the effectiveness of Enteral Long-Chain Polyunsaturated Fatty Acids (LCPUFA) was reviewed in the prevention of ROP and related outcomes. The primary studies were graded very low to low on various outcomes based on GRADE. The findings revealed LCPUFA was not effective in preventing any type of ROP (RR=0.95, 95% CI 0.73 to 1.12). However, there was a trend

toward benefit in mitigating severe form of ROP (stage  $\geq 3$ ) with an RR of 0.59 (95% CI 0.35 to 0.99).<sup>53, level I</sup>

#### 6.4 Treatment of Aggressive Retinopathy of Prematurity

AROP is a rapidly progressive form of ROP. If not treated, the disease can progress to stage 5 ROP.

A multicentre cohort study evaluated the preference of the treating ophthalmologist and treatment outcomes between anti-VEGF and laser photocoagulation as primary and additional treatment in AROP and Type 1 ROP. The findings showed:<sup>54, level II-2</sup>

- anti-VEGF was selected when the ROP was located in zone I or posterior zone II, while laser photocoagulation when it was located in zone II
- infants with AROP were twice more likely to require additional treatment than those with Type 1 ROP
- when ROP reactivation occurred, laser photocoagulation was preferred as an additional treatment
- eyes receiving additional treatment were due to inadequate treatment and reactivation of ROP

An RCT reported the treatment outcomes of early (1-week post-intravitreal ranibizumab) vs deferred (6-weeks post-intravitreal ranibizumab) laser photocoagulation in infants of AROP after initial treatment with intravitreal ranibizumab. The findings were:<sup>55, level I</sup>

- no significant difference in favourable structural outcomes (complete regression) between the two groups at six weeks
- eyes undergoing deferred laser had significantly fewer number of laser spots and less myopia at six months after laser treatment

However, there was no blinding and intention-to-treat analysis mentioned in the paper.

In a small cross-sectional study on APROP treated with intravitreal ranibizumab injection, there was 100% success in retinal attachment and disappearance of neovascularisation.<sup>56, level III</sup>

In the clinical guidelines on treating ROP in UK, treatment-requiring APROP and ROP in zone I should be treated with an intravitreal injection of an anti-VEGF agent.<sup>34</sup>

#### Recommendation 9

- Anti-vascular endothelial growth factor (anti-VEGF) is the preferred choice in treating aggressive retinopathy of prematurity.

## **6.5 Rescue Treatment**

Based on the evidence discussed above, treatment of ROP depends on ROP subtypes, location and reactivation. Laser therapy is the gold standard treatment for ROP located in zone II. Anti-VEGFs are preferred primary treatment in AROP and posterior disease. If rescue treatment is required, either laser photocoagulation or anti-VEGF may be selected.<sup>44 level I; 55, level I</sup>

## 7. MONITORING AND DISCHARGE CRITERIA FOR RETINOPATHY OF PREMATURITY SCREENING

The follow-up of ROP screened infants forms a crucial burden on the healthcare system as well as time consuming for parents in bringing their infants for frequent follow-up. Thus, it is important to identify the subgroup of ROP screened infants who require long-term follow-up and those who can be safely discharged to existing healthcare system.

In a prospective cohort study done prior to ETROP on infants with BW  $\leq 1500$  g who underwent ROP screening until the subjects reached 10 years of age, 25% had visual dysfunction. Neurological complications, cryotreated ROP and anisometropia were risk factors for predicting visual dysfunction.<sup>57, level II-2</sup>

Another prospective cohort study with seven years follow-up showed that patients with severe ROP rapidly progressed toward myopia, particularly during the first 1.3 years, compared with those with mild/no ROP.<sup>26, level II-2</sup>

In a case-control study which compared spontaneously regressed ROP (zone II and III) and no ROP, the mean PMA at first cycloplegic refraction was  $7.5 \pm 4.0$  months. The main findings were:<sup>58, level II-2</sup>

- 21.9% of spontaneously-regressed ROP developed myopia compared with 8.8% eyes without ROP
- among those with spontaneously regressed ROP with vascularisation halted at zone II, 44% had myopia
- SE differed by zone of retinal vascularisation ( $p < 0.0001$ )

Thus, infants with halted vascular growth in zone II should be closely monitored for myopia.

In another case-control study comparing ROP cases which had resolved by 50 weeks vs those resolved beyond 50 weeks, significant factors associated with delayed resolution were:<sup>59, level II-2</sup>

- increasing severity of ROP (higher stage, lower zone, plus/pre-plus disease)
- Type 2 ROP
- $< 28$  weeks gestational age
- third percentile BW on Fenton preterm birth chart
- positive blood culture sepsis
- NEC
- intraventricular haemorrhage
- bronchopulmonary dysplasia

No infant developed Type 1 ROP after 50 weeks PMA.

Two retrospective cohort studies looked into the outcomes of treated ROP. In the first study on 115 babies with stage-3 ROP persisting



beyond 40-weeks of PMA, a vast majority of 80.8% eyes with ROP resolved spontaneously while 19.2% eyes were treated with laser-photocoagulation. Apart from that, majority of eyes with stage 3 ROP (89.5%) resolved by 50 weeks while the remainder resolved by 61 weeks PMA.<sup>60, level II-2</sup>

The second smaller study on 28 eyes of Type 1 ROP treated with intravitreal bevacizumab showed that all completely regressed by four weeks. Within the first three months, 60.7% eyes developed recurrence to stage 1 or 2 after regression. At a mean of 24 months, 39% of eyes were not vascularised into zone III as seen on fluorescein angiography with scleral indentation.<sup>61, level II-2</sup>

The UK Screening of ROP guideline recommends that infants without ROP should have continued examinations until vascularisation has extended into zone III.<sup>11</sup> The CPG DG opines that screening should be done until the retina is completely vascularised.

#### **Recommendation 10**

- Discharge from retinopathy of prematurity screening should be done when retina is completely vascularised.

## 8. FOLLOW-UP

An RCT, which is part of ETROP, examined the prevalence of myopia and high myopia at 6- and 9-month post-term and, 2- and 3-year postnatal findings. It showed:<sup>62, level I</sup>

- prevalence of myopia at 6- and 9-month post-term were significantly higher in conventional management eyes than in early treated eyes; however, there was no difference in the prevalence of high myopia
- prevalence of myopia and high myopia were similar at 2- and 3-year postnatal
- in both treatment groups, there was an increase in prevalence of myopia over time, occurring mostly between 6- and 9-month post-term while in contrast, prevalence of high myopia increased at each successive age up to three years

A prospective cohort study evaluated the extent to which refractive morbidity at six and 24 months of PMA is correlated to preterm birth or ROP compared with full-term infants. Those with laser-treated severe ROP had the highest prevalence of refractive errors during the first two years of life. The refractive errors increased significantly across the ages and these findings indicated that monitoring on it was required for at least two years. Furthermore, SE in eyes with regressed ROP and those without ROP was significantly lower than eyes of full-term infants at the first refraction (six months). However, there was no difference in the prevalence of refractive errors at age of two years among those without ROP, with regressed ROP and full-term infants. The study also suggested that spontaneously regressed ROP and no ROP should not be used as a criterion for follow-up examinations of refractive errors during the first two years of life.<sup>63, level II-2</sup>

In a retrospective observational study on changes in refractive errors in preterm infants with and without ROP in the first six years of life, significant increase in myopia values was noted only between first and third-year examinations in the severe ROP (treated) group. However, no significant trend was observed in the mild/no ROP groups. There was also no significant trend in astigmatism and anisometropia seen in both mild/no and severe ROP groups.<sup>64, level III</sup>

A recent retrospective study in Taiwan showed that approximately one-third of ROP eyes with spontaneous regression or anti-VEGF injection exhibited persistent avascular retina when the children reached school age.<sup>65, level II-2</sup> Thus, this indicates that patients with regressed ROP have long-term risk for ROP-related complications. Parental counselling with regard to this complication is essential.

Based on the above evidence and expert opinion, the CPG DG proposes the following follow-up schedule as shown in the following table.

| Outcomes of ROP   | Follow-up and Assessment  |
|---|---|
| Infants with no ROP   | <ul style="list-style-type: none"> <li>• Complete eye examination* at 6 months of age:               <ul style="list-style-type: none"> <li>○ if normal - VA at 4 years of age</li> <li>○ if abnormal - consult ophthalmologist</li> </ul> </li> </ul>  |
| Infants with spontaneous regression and fully vascularised                      | <ul style="list-style-type: none"> <li>• Complete eye examination* at 6 months of age:               <ul style="list-style-type: none"> <li>○ if normal - VA at 4 years of age</li> <li>○ if abnormal - consult ophthalmologist</li> </ul> </li> </ul>  |
| Infants treated with laser photocoagulation or anti-VEGF and fully vascularised | <ul style="list-style-type: none"> <li>• Complete eye examination* at 6 months of age:               <ul style="list-style-type: none"> <li>○ if normal - yearly examination until 5 years of age</li> <li>○ if abnormal - consult ophthalmologist</li> <li>○ for laser treated infants, baseline visual field assessment may be performed based on the discretion of the treating ophthalmologist</li> </ul> </li> </ul> |
| Infants with PAR  | <ul style="list-style-type: none"> <li>• Regular follow-up at the discretion of the ophthalmologist with the possibility of fundus fluoresceine angiography (FFA) and laser photocoagulation</li> </ul>   |

\*consists of VA, alignment, nystagmus, cycloplegic refraction and dilated fundoscopy

#### Recommendation 11

- Follow-up of infants with or without retinopathy of prematurity (ROP) should be done accordingly with complete eye examination\* based on staging and treatment given

\*Refer to the above table

## 9. REHABILITATION

ROP is a globally important cause of childhood severe VI/blindness. Paediatricians and other paediatric professionals have a key role in its early detection and multidisciplinary management to minimise the impact of VI in childhood. These include:<sup>66, level III</sup>

- **Certification and registration of childhood visual impairment**  
Certification of VI by the ophthalmologist will enable registration of the child at the social services or an equivalent governmental body for educational and welfare support.
- **Educational support**  
Early referral/notification of children with severe VI/blindness allows involvement of specialised educational support. Assessment and prescription of optical and non-optical low vision aid could be provided.

Low vision rehabilitation in children with VI including those with ROP improves significantly:<sup>67, level II-3</sup>

- VA for distance and near vision
- functional vision in relation to studying/reading lifestyle, reading textbook at arm's length, writing along a straight line and other generalised activities

A recent RCT showed that early visual training (along with environmental adaptations and high social engagement) improved vision-related performance and specific aspects of neurological development outcomes in infants with both peripheral and cerebral VI.<sup>68, level I</sup>

In the local setting, infants with low vision/blindness should be referred to occupational therapy for an early intervention programme in the respective healthcare facility. Older children should have access to all relevant rehabilitation services. They should also be registered with the Jabatan Kebajikan Masyarakat (Department of Social Welfare) for placement in special education. Refer to **Appendix 11**. Malaysian Association for the Blind and other relevant non-governmental organisations providing training/support for these children.

### Recommendation 12

- Visual rehabilitation should be provided to all visually-impaired children.

## **10. IMPLEMENTING THE GUIDELINES**

The management of ROP should be guided by evidence-based approach in order to provide quality care to the patients. Several factors may affect the implementation of recommendations in the CPG.

### **10.1 Facilitating and Limiting Factors**

Existing facilitators for application of the recommendations in the CPG include:

- wide dissemination of the CPG (soft- and hardcopies) to healthcare providers and institutions
- training and updates on the management of ROP in relevant scientific and professional meeting, seminar, conference etc.
- Malaysian National Neonatal Registry which includes data on ROP by MoH hospitals and Vermont Oxford Network by MoHE hospitals

Existing barriers for application of the recommendations of the CPG are:

- limited awareness and knowledge among healthcare providers on ROP and its management
- lack of awareness and understanding among parents/carers on the importance of prematurity and risk of ROP
- lack of expertise and facilities in diagnosing ROP and delivering its treatment

### **10.2 Potential Resource Implications**

Although ROP is uncommon, it is a treatable condition. Early identification is crucial as early treatment will provide favourable visual outcomes including prevention of blindness.

Screening on preterm infants at risk of ROP is strongly advocated. Trained ophthalmologists, other healthcare professionals (neonatologists/paediatricians) and nurses are required in the screening. BIO is currently the gold standard method of screening, however there is emerging evidence on the potential use of digital imaging techniques and telemedicine which require financial and infrastructural support. Regular screening is essential until the retina has matured and no complications developed.

The main options for treatment of ROP is laser photocoagulation and anti-VEGF. The latter requires skilled ophthalmologist and the availability of the medications. Apart from that, patient may need to be referred to a secondary or tertiary centre for further treatment. Visual

rehabilitation is an important component in the long-term management of ROP. In summary, screening, diagnosis, treatment, follow-up and rehabilitation in ROP has resource implications in their implementation.

The following is proposed as clinical audit indicator for quality management of ROP:

- Percentage of infants at risk of ROP\* having first examination to detect ROP based on PMA and PNA

$$= \frac{\text{Number of infants at risk of ROP having first examination to detect ROP based on PMA and PNA in a period}}{\text{Number of infants at risk of ROP having first examination to detect ROP in the same period}} \times 100\%$$

Implementation strategies will be developed following the approval of the CPG by MoH which include quick reference, launching of the CPG and, Training Module and training of healthcare providers in using it.

## References

1. Malaysian National Neonatal Registry and Clinical Research Centre, Ministry of Health Malaysia, Kuala Lumpur 2019.
2. Ministry of Health. Management of Retinopathy of Prematurity. Kuala Lumpur: MoH; 2005
3. Good WV. Final results of the Early Treatment for Retinopathy of Prematurity (ETROP) randomized trial. *Trans Am Ophthalmol Soc.* 2004;102:233-48; discussion 48-50.
4. Ahn YJ, Hong KE, Yum HR, et al. Characteristic clinical features associated with aggressive posterior retinopathy of prematurity. *Eye (Lond).* 2017;31(6):924-30.
5. Razak A, Faden M. Association of small for gestational age with retinopathy of prematurity: a systematic review and meta-analysis. *Arch Dis Child Fetal Neonatal Ed.* 2020;105(3):270-8.
6. Gantz MG, Carlo WA, Finer NN, et al. Achieved oxygen saturations and retinopathy of prematurity in extreme preterms. *Arch Dis Child Fetal Neonatal Ed.* 2020;105(2):138-144.
7. Askie LM, Darlow BA, Finer N, et al. Association Between Oxygen Saturation Targeting and Death or Disability in Extremely Preterm Infants in the Neonatal Oxygenation Prospective Meta-analysis Collaboration. *Jama.* 2018;319(21):2190-201.
8. Zhu Z, Hua X, Yu Y, et al. Effect of red blood cell transfusion on the development of retinopathy of prematurity: A systematic review and meta-analysis. *PLoS One.* 2020;15(6):e0234266.
9. Wang X, Tang K, Chen L, et al. Association between sepsis and retinopathy of prematurity: a systematic review and meta-analysis. *BMJ Open.* 2019;9(5):e025440.
10. Fundora JB, Binenbaum G, Tomlinson L, et al. Association of Surgical Necrotizing Enterocolitis and its Timing with Retinopathy of Prematurity. *Am J Perinatol.* 2023;40(11):1178-1184
11. The Royal College of Paediatrics and Child Health (RCPC) and the Royal College of Ophthalmologists (RCOphth). UK screening and treatment of retinopathy of prematurity. Updated 2022 Guidelines. *Early Hum Dev.* 2023;177-178:105715
12. Section on Ophthalmology American Academy of Pediatrics; American Academy of Ophthalmology; American Association for Pediatric Ophthalmology and Strabismus. Screening examination of premature infants for retinopathy of prematurity. *Pediatrics.* 2006;117(2):572-6
13. Yu CW, Popovic MM, Dhoot AS, et al. Demographic Risk Factors of Retinopathy of Prematurity: A Systematic Review of Population-Based Studies. *Neonatology.* 2022;119(2):151-63.
14. Gilbert C, Fielder A, Gordillo L, et al. Characteristics of infants with severe retinopathy of prematurity in countries with low, moderate, and high levels of development: implications for screening programs. *Pediatrics.* 2005;115(5):e518-25.
15. Xu Y, Zhou X, Zhang Q, et al. Screening for retinopathy of prematurity in China: a neonatal units-based prospective study. *Invest Ophthalmol Vis Sci.* 2013;54(13):8229-36.
16. Yang Q, Zhou X, Ni Y, et al. Optimised retinopathy of prematurity screening guideline in China based on a 5-year cohort study. *Br J Ophthalmol.* 2021;105(6):819-23.
17. Jalali S, Krishnan DB. Counselling and co-opting parents to get best outcomes. *Community Eye Health.* 2018;31(101):S29-S31.

18. The Royal College of Ophthalmologists. Information leaflet for parents and guardians - Treatment-for-Retinopathy of Prematurity (Available at: [www.rcophth.ac.uk](http://www.rcophth.ac.uk))
19. Kremer LJ, Reith DM, Medicott N, et al. Systematic review of mydriatics used for screening of retinopathy in premature infants. *BMJ Paediatr Open*. 2019;3(1):e000448.
20. Sun X, Lemyre B, Barrowman N, et al. Pain management during eye examinations for retinopathy of prematurity in preterm infants: a systematic review. *Acta Paediatr*. 2010;99(3):329-34.
21. Costa MC, Eckert GU, Fortes BG, et al. Oral glucose for pain relief during examination for retinopathy of prematurity: a masked randomized clinical trial. *Clinics (Sao Paulo)*. 2013;68(2):199-204.
22. Athikarismy SE, Patole S, Lam GC, et al. Screening for retinopathy of prematurity (ROP) using wide-angle digital retinal photography by non-ophthalmologists: a systematic review. *Br J Ophthalmol*. 2015;99(3):281-8.
23. Sekeroglu MA, Hekimoglu E, Sekeroglu HT, et al. Alternative methods for the screening of retinopathy of prematurity: binocular indirect ophthalmoscopy vs wide-field digital retinal imaging. *Eye (Lond)*. 2013;27(9):1053-7.
24. Athikarismy SE, Lam GC, Ross S, et al. Comparison of wide field imaging by nurses with indirect ophthalmoscopy by ophthalmologists for retinopathy of prematurity: a diagnostic accuracy study. *BMJ Open*. 2020;10(8):e036483.
25. Photographic Screening for Retinopathy of Prematurity (Photo-ROP) Cooperative Group. The photographic screening for retinopathy of prematurity study (photo-ROP). Primary outcomes. *Retina*. 2008;28(3 Suppl):S47-54.
26. Wang J, Ren X, Shen L, et al. Development of refractive error in individual children with regressed retinopathy of prematurity. *Invest Ophthalmol Vis Sci*. 2013;54(9):6018-24.
27. Vinekar A, Gilbert C, Dogra M, et al. The KIDROP model of combining strategies for providing retinopathy of prematurity screening in underserved areas in India using wide-field imaging, tele-medicine, non-physician graders and smart phone reporting. *Indian J Ophthalmol*. 2014;62(1):41-9.
28. Chiang MF, Quinn GE, Fielder AR, et al. International Classification of Retinopathy of Prematurity, Third Edition. *Ophthalmology*. 2021;128(10):e51-e68.
29. Good WV, Hardy RJ, Dobson V, et al. The incidence and course of retinopathy of prematurity: findings from the early treatment for retinopathy of prematurity study. *Pediatrics*. 2005;116(1):15-23.
30. Christiansen SP, Dobson V, Quinn GE, et al. Progression of type 2 to type 1 retinopathy of prematurity in the Early Treatment for Retinopathy of Prematurity Study. *Arch Ophthalmol*. 2010;128(4):461-5.
31. Austeng D, Källén KB, Hellström A, et al. Natural history of retinopathy of prematurity in infants born before 27 weeks' gestation in Sweden. *Arch Ophthalmol*. 2010;128(10):1289-94.
32. Wang L, Li M, Zhu J, et al. Clinical Features of Spontaneous Regression of Retinopathy of Prematurity in China: A 5-Year Retrospective Case Series. *Front Med (Lausanne)*. 2021;8:731421.
33. Ni YQ, Huang X, Xue K, et al. Natural involution of acute retinopathy of prematurity not requiring treatment: factors associated with the time course of involution. *Invest Ophthalmol Vis Sci*. 2014;55(5):3165-70.
34. The Royal College of Ophthalmologists. Treating Retinopathy of Prematurity in the UK. London: RCOPHTH; 2022.
35. Roohipourmoallai R, Faghihi S, Faghihi H, et al. Transscleral vs transpupillary diode laser photocoagulation for the treatment of zone II type 1 retinopathy of prematurity: Anatomical and refractive outcomes. *Indian J Ophthalmol*. 2022;70(1):189-93.



36. Yalin Imamoglu E, Gunay M, GURSOY T, et al. Effect of laser photocoagulation on plasma levels of VEGF-A, VEGFR-2, and Tie2 in infants with retinopathy of prematurity. *J AAPOS*. 2014;18(5):466-70.
37. Bremer DL, Rogers DL, Good WV, et al. Glaucoma in the Early Treatment for Retinopathy of Prematurity (ETROP) study. *J AAPOS*. 2012;16(5):449-52.
38. Davitt BV, Christiansen SP, Hardy RJ, et al. Incidence of cataract development by 6 months' corrected age in the Early Treatment for Retinopathy of Prematurity study. *J AAPOS*. 2013;17(1):49-53.
39. Li Z, Zhang Y, Liao Y, et al. Comparison of efficacy between anti-vascular endothelial growth factor (VEGF) and laser treatment in Type-1 and threshold retinopathy of prematurity (ROP). *BMC Ophthalmol*. 2018;18(1):19.
40. Taher NO, Ghaddaf AA, Al-Ghamdi SA, et al. Intravitreal Anti-vascular Endothelial Growth Factor Injection for Retinopathy of Prematurity: A Systematic Review and Meta-Analysis. *Front Med (Lausanne)*. 2022;9:884608.
41. Sankar MJ, Sankar J, Chandra P. Anti-vascular endothelial growth factor (VEGF) drugs for treatment of retinopathy of prematurity. *Cochrane Database Syst Rev*. 2018;1(1):CD009734.
42. Tan QQ, Christiansen SP, Wang J. Development of refractive error in children treated for retinopathy of prematurity with anti-vascular endothelial growth factor (anti-VEGF) agents: A meta-analysis and systematic review. *PLoS One*. 2019;14(12):e0225643.
43. Natarajan G, Shankaran S, Nolen TL, et al. Neurodevelopmental Outcomes of Preterm Infants With Retinopathy of Prematurity by Treatment. *Pediatrics*. 2019;144(2):2018-3537
44. Stahl A, Lepore D, Fielder A, et al. Ranibizumab versus laser therapy for the treatment of very low birthweight infants with retinopathy of prematurity (RAINBOW): an open-label randomised controlled trial. *Lancet*. 2019;394(10208):1551-9.
45. Marlow N, Stahl A, Lepore D, et al. 2-year outcomes of ranibizumab versus laser therapy for the treatment of very low birthweight infants with retinopathy of prematurity (RAINBOW extension study): prospective follow-up of an open label, randomised controlled trial. *Lancet Child Adolesc Health*. 2021;5(10):698-707.
46. Eilts SK, Pfeil JM, Poschkamp B, et al. Assessment of Retinopathy of Prematurity Regression and Reactivation Using an Artificial Intelligence-Based Vascular Severity Score. *JAMA Netw Open*. 2023;6(1):e2251512.
47. Palmer EA, Hardy RJ, Dobson V, et al. 15-year outcomes following threshold retinopathy of prematurity: final results from the multicenter trial of cryotherapy for retinopathy of prematurity. *Arch Ophthalmol*. 2005;123(3):311-8.
48. Macor S, Pignatto S, Capone A, Jr., et al. Lens-sparing vitrectomy for stage 4A retinopathy of prematurity in infants with aggressive-posterior ROP: Anatomic and functional results. *Eur J Ophthalmol*. 2021;31(4):2020-6.
49. Sen P, Bhende P, Sharma T, et al. Surgical outcomes of microincision vitrectomy surgery in eyes with retinal detachment secondary to retinopathy of prematurity in Indian population. *Indian J Ophthalmol*. 2019;67(6):889-95.
50. Ratanasukon M, Visaetsilpanonta S, Tengtrisorn S, et al. Outcomes of scleral buckling for stage 4 retinopathy of prematurity in Thai children. *J Med Assoc Thai*. 2006;89(10):1659-64.
51. Shah RJ, Garcia-Gonzalez JM, Blair MP, et al. Concurrent Scleral Buckle and Intravitreal Bevacizumab for Advanced Retinopathy of Prematurity- Related Retinal Detachment. *Retin Cases Brief Rep*. 2016;10(2):183-6.
52. Kaempfen S, Neumann RP, Jost K, et al. Beta-blockers for prevention and treatment of retinopathy of prematurity in preterm infants. *Cochrane Database Syst Rev*. 2018;3(3):CD011893.

53. Diggikar S, Aradhya AS, Swamy RS, et al. Effect of Enteral Long-Chain Polyunsaturated Fatty Acids on Retinopathy of Prematurity: A Systematic Review and Meta-Analysis. *Neonatology*. 2022;119(5):547-57.
54. Jang JH, Kang YK, Park HS, et al. Primary and additional treatment preference in aggressive retinopathy of prematurity and type 1 retinopathy of prematurity. *BMJ Open Ophthalmology*. 2023;8(1):e001166.
55. Gangwe AB, Agrawal D, Gangrade AK, et al. Outcomes of early versus deferred laser after intravitreal ranibizumab in aggressive posterior retinopathy of prematurity. *Indian J Ophthalmol*. 2021;69(8):2171-6.
56. Sahinoglu-Keskek N, Akkoyun I, Torer B. Favorable outcomes in the treatment of aggressive posterior retinopathy of prematurity. *Eur J Ophthalmol*. 2021;31(1):179-83.
57. Holmström G, Larsson E. Long-term follow-up of visual functions in prematurely born children--a prospective population-based study up to 10 years of age. *J AAPOS*. 2008;12(2):157-62.
58. Dikopf MS, Machen LA, Hallak JA, et al. Zone of retinal vascularization and refractive error in premature eyes with and without spontaneously regressed retinopathy of prematurity. *J AAPOS*. 2019;23(4):211.e1-211.e6.
59. Ahmad M, Patnaik J, Thevarajah T, et al. Delayed resolution of retinopathy of prematurity. *J AAPOS*. 2019;23(2):90.e1-90.e6.
60. Koucheiki R, Isaac M, N NT, et al. Natural history and outcomes of stage 3 retinopathy of prematurity persisting beyond 40 weeks of post-menstrual age: Dilemma for treatment and follow up. *Clin Exp Ophthalmol*. 2020;48(7):956-63.
61. Isaac M, Tehrani N, Mireskandari K. Involution patterns of retinopathy of prematurity after treatment with intravitreal bevacizumab: implications for follow-up. *Eye (Lond)*. 2016;30(3):333-41.
62. Quinn GE, Dobson V, Davitt BV, et al. Progression of myopia and high myopia in the early treatment for retinopathy of prematurity study: findings to 3 years of age. *Ophthalmology*. 2008;115(6):1058-64.e1.
63. Hsieh CJ, Liu JW, Huang JS, et al. Refractive outcome of premature infants with or without retinopathy of prematurity at 2 years of age: a prospective controlled cohort study. *Kaohsiung J Med Sci*. 2012;28(4):204-11.
64. Kaya M, Berk AT, Yaman A. Long-term evaluation of refractive changes in eyes of preterm children: a 6-year follow-up study. *Int Ophthalmol*. 2018;38(4):1681-8.
65. Ling XC, Kang EY, Huang JL, et al. Persistent Vascular Anomalies in Retinopathy of Prematurity Children: Ultrawide-field Fluorescein Angiography Findings until School Age. *Ophthalmol Sci*. 2023;3(3):100281.
66. Solebo AL, Rahi J. Epidemiology, aetiology and management of visual impairment in children. *Arch Dis Child*. 2014;99(4):375-9.
67. Ganesh S, Sethi S, Srivastav S, et al. Impact of low vision rehabilitation on functional vision performance of children with visual impairment. *Oman J Ophthalmol*. 2013;6(3):170-4.
68. Fazzi E, Micheletti S, Calza S, et al. Early visual training and environmental adaptation for infants with visual impairment. *Dev Med Child Neurol*. 2021;63(10):1180-93.

## Appendix 1

### EXAMPLE OF SEARCH STRATEGY

**Clinical Question:** What are the effectiveness and safety of laser therapy in retinopathy of prematurity?

1. RETINOPATHY OF PREMATUREITY/
2. (Retrolental adj1 fibroplasia\*).tw.
3. (Prematurity adj1 retinopath\*).tw.
4. LASER COAGULATION/
5. (laser adj1 coagulation\*).tw.
6. (laser adj1 thermocoagulation\*).tw.
7. 1 or 2 or 3
8. 4 or 5 or 6
9. 7 and 8
10. limit 9 to (english language and humans and "all infant (birth to 23 months)" and last 18 years)

**CLINICAL QUESTIONS**

1. Who should be screened for retinopathy of prematurity?
2. What is the optimum timing for screening retinopathy of prematurity?
3. What is the accuracy of screening methods for retinopathy of prematurity?
  - clinical
  - imaging
4. What is the classification for retinopathy of prematurity?
5. What are the risk factors for severe retinopathy of prematurity?
6. What are the natural course of the disease in retinopathy of prematurity?
7. What are the indications for treatment of retinopathy of prematurity?
8. What is the optimum timing for treatment of retinopathy of prematurity?
9. What are the effectiveness and safety of the following treatment in retinopathy of prematurity?
  - laser therapy
  - intravitreal anti-vascular endothelial growth factor
  - cryotherapy
  - vitreoretinal surgery - vitrectomy and scleral buckle
  - adjunctive treatment
    - orbital floor corticosteroids
    - topical nonsteroidal anti-inflammatory drugs
    - topical corticosteroids
10. What are the discharged and monitoring criteria in retinopathy of prematurity with the following features?
  - premature babies
    - prematurity less than 30 weeks
    - without retinopathy of prematurity
      - fully vascularised retina
      - incomplete vascularised retina
  - babies with BW less than 1.5 kg
11. What is the effective follow-up schedule in retinopathy of prematurity with the following features?

- treated
  - non-treated
  - parameters at follow-up
  - reactivation and regression
  - use of artificial intelligence/imaging
12. What are the effective/components of counselling for retinopathy of prematurity with the following features to parents/caregivers?
- all babies at risk
  - infants that require treatment
  - on long term follow-up
13. What are the effective rehabilitation methods of different period in retinopathy of prematurity?
- short-term (vision)
  - long-term (special vocational training)

## Appendix 3

OPTIMUM TIMING FOR FIRST RETINOPATHY OF  
PREMATURITY SCREENING

| GA (weeks) | PMA (weeks) | PNA (weeks) |
|------------|-------------|-------------|
| 22         | 31          | 9           |
| 23         | 31          | 8           |
| 24         | 31          | 7           |
| 25         | 31          | 6           |
| 26         | 31          | 5           |
| 27         | 31          | 4           |
| 28         | 32          | 4           |
| 29         | 33          | 4           |
| 30         | 34          | 4           |
| 31         | 35          | 4           |
| >32        | 36          | -           |

GA: gestational age, PMA: postmenstrual age, PNA: postnatal age, BW: birth weight, g; gram

**Source:** Wilkinson AR, Adams GGW, Fleck BW, et al. UK screening and treatment of retinopathy of prematurity Updated 2022 Guidelines. *Early Hum Dev.* 2023;177-178:105715.

### ALTERNATIVE DILATING REGIMES

The dilating regime stated here is adopted from local practice of Paediatric Ophthalmology Department of Hospital Tunku Azizah (Kuala Lumpur Women and Children Hospital), the national's main tertiary referral centre.

In local clinical practice, the infants are usually kept fasted from the time of dilatation. Excess drops are needed to be wiped off to reduce systemic absorption and side effects.

| Time interval               | Suggested eyedrops regime*  |
|-----------------------------|---|
| <b>0 min</b>                | Gutt proparacaine 0.5% one drop<br>Gutt tropicamide 1% one drop<br>Gutt phenylephrine 2.5% one drop |
| <b>10 min</b>               | If eye(s) not fully dilated, top up with: Gutt tropicamide 1% one drop                              |
| <b>20 min</b>               | If eye(s) not fully dilated, top up with: Gutt phenylephrine 2.5% one drop                          |
| <b>30 min</b>               | If eye(s) not fully dilated, top up with: Gutt tropicamide 1% one drop                              |
| <b>40 min</b>               | If eye(s) still not fully dilated, to rule out causes of poor pupillary dilatation                  |
| <b>Once fully dilated**</b> | Gutt proparacaine 0.5% prior to ROP examination   |

\*vital signs monitoring is required for in-patient during dilating process (pre-ROP examinations) as well as during ROP examination

\*\*consider giving oral sucrose for supplementary pain relief

### PHARMACOKINETICS AND PHARMACODYNAMICS OF DILATING AGENTS

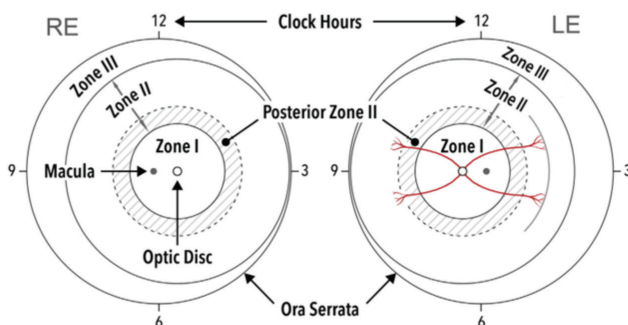
| NO. | DILATING AGENTS                        | PHARMACOKINETICS  | PHARMACODYNAMICS (MECHANISM OF ACTION)   |
|-----|--|---|--|
| 1.  | Cyclopentolate 1% Ophthalmic Solution  | Rapid onset, maximal cycloplegia occurs within 25 - 75 minutes after instillation. Complete recovery of accommodation usually takes 6 - 24 hours. Complete recovery from mydriasis in some individuals may require several days. Heavily pigmented irides may require more doses than lightly pigmented irides. | Cyclopentolate hydrochloride is an anticholinergic ophthalmic preparation that blocks the responses of the sphincter muscle of the iris and the stimulation of the ciliary body muscle achieving mydriasis and cycloplegia.  |
| 2.  | Tropicamide 1% Ophthalmic Solution     | Mydriasis occur in 15 - 30 minutes and the duration of activity is approximately 3 - 8 hours. Complete recovery from mydriasis in some individuals may require 24 hours.  | Ophthalmic: Tropicamide is an anticholinergic agent that blocks the responses of the sphincter muscle of the iris and the accommodative muscle of the ciliary body to stimulation by acetylcholine. The 1% solution produces paralysis of accommodation (cycloplegia) as well as mydriasis.  |
| 3.  | Phenylephrine 2.5% Ophthalmic Solution | Maximal mydriasis occurs in 20 - 90 minutes with recovery after 3 - 8 hours. Systemic absorption of sufficient quantities of phenylephrine may lead to systemic $\alpha$ -adrenergic effects, such as rise in blood pressure which may be accompanied by a reflex atropine-sensitive bradycardia.               | Phenylephrine hydrochloride is an $\alpha$ -1 adrenergic agonist drug that is used in ophthalmology mainly for its mydriatic effect. After topical application to the conjunctiva, phenylephrine acts directly on $\alpha$ -adrenergic receptors in the eye, producing contraction of the dilator muscle of the pupil and constriction of the arterioles in the conjunctiva. |



| NO. | DILATING AGENTS   | PHARMACOKINETICS   | PHARMACODYNAMICS (MECHANISM OF ACTION)   |
|-----|---|--|--|
| 4.  | <p>CYCLOMYDRIL<br/>(Cyclopentolate hydrochloride 0.2% and phenylephrine hydrochloride 1.0%)<br/>Ophthalmic Solution</p> | <p><b>Absorption</b></p> <ul style="list-style-type: none"> <li>• Following topical ocular administration, cyclopentolate is absorbed into the eye as well as the systemic circulation. Peak plasma drug concentrations range from 3.3 to 15.5 ng/mL (mean: 8.3±4.1 ng/mL) and are achieved within 5 - 15 minutes following the second dose.</li> <li>• Following topical ocular administration, phenylephrine is absorbed into the eye as well as the systemic circulation.</li> </ul> <p><b>Distribution</b></p> <ul style="list-style-type: none"> <li>• Ocular and systemic distribution of cyclopentolate has not been reported.</li> </ul> <p><b>Biotransformation</b></p> <ul style="list-style-type: none"> <li>• The metabolic pathways of cyclopentolate have not been reported in the literature.</li> <li>• Phenylephrine is primarily metabolised by conjugation, primarily as the sulfate with smaller amounts of glucuronide also formed.</li> </ul> <p><b>Elimination</b></p> <ul style="list-style-type: none"> <li>• The elimination mechanisms of cyclopentolate have not been reported in the literature.</li> <li>• Phenylephrine is primarily eliminated in the urine, primarily as the sulfate conjugate with smaller amounts of the glucuronide. Virtually no free parent drug is found in urine.</li> </ul> | <p>Cyclopentolate is an anticholinergic drug and phenylephrine is an adrenergic drug. This combination induces mydriasis that is greater than that of either drug alone at its respective concentrations. The concentrations of cyclopentolate hydrochloride and phenylephrine hydrochloride have been selected to induce mydriasis with little accompanying cycloplegia. Heavily pigmented irides may require more doses than lightly pigmented irides.</p> |

Source: Product Insert of the respective dilating agents.

### SUMMARY OF KEY COMPONENTS OF INTERNATIONAL CLASSIFICATION OF RETINOPATHY OF PREMATURITY THIRD EDITION



The figure above illustrates retinal zones for ROP of right (RE) and left eye (LE) showing zone borders and clock hour sectors used to describe the location of vascularisation and extent of retinopathy. Solid circles represent borders of zones I through III, and dotted circles represent borders of posterior zone II (2 disc diameters beyond zone I).

An example of examination findings is shown in LE, representing approximately 3 clock hours of stage 1 disease in zone II (note single line on drawing to document presence of stage 1 disease).

The description of the zones for classification of ROP are as follows:

- Zone I extends from the optic disc to a point double the distance from the disc to the fovea, a radius of 30°.
- Zone II is a circle surrounding the zone I circle with the nasal ora serrata as its nasal border.
- Zone III is the residual crescent anterior to zone II.

|  |  |
|--|--|
| <p><b>1. Zone (additional description)</b></p> | <p>a. Definition of 3 retinal zones centred on the optic disc. The location of the most posterior retinal vascularisation or ROP lesion denotes the zone for the eye.</p> <p>b. Definition of a posterior zone II region that begins at the margin between zone I and zone II and extends into zone II for 2 disc diameters.*</p> <p>c. The term notch is used to describe an incursion by the ROP lesion of 1 - 2 clock hours into a more posterior zone. The</p> |
|--|--|

|   |   |
|---|---|
|   | ROP zone for such eyes should be noted by the most posterior zone of retinal vascularisation with the qualifier “notch” (e.g., “zone I secondary to notch”).*   |
| <b>1. Plus and Pre-plus Disease</b>             | <p>Plus disease is defined by the appearance of dilation and tortuosity of retinal vessels, and</p> <p>Pre-plus disease is defined by abnormal vascular dilation, tortuosity insufficient for plus disease, or both.</p> <p>Recognition that retinal vascular changes in ROP represent a continuous spectrum from normal to pre-plus to plus disease, with sample images demonstrating this range.* These changes should be assessed by vessels within zone I, rather than from only vessels within the field of narrow-angle photographs and rather than from the number of quadrants of abnormality.*</p>                 |
| <b>2. Stage of Acute Disease (Stages 1 - 3)</b> | <p>Stage 1: Demarcation line</p> <p>Stage 2: Ridge</p> <p>Stage 3: Extraretinal neovascular proliferation or flat neovascularisation</p> <p>If more than 1 ROP stage is present, the eye is classified by the most severe stage.</p>  |
| <b>3. Retinal Detachment (Stages 4 and 5)</b>   | <p>Stages of RD are defined as</p> <p>a. Stage 4 (partial RD)</p> <p>4A: with fovea attached</p> <p>4B: with fovea detached</p> <p>b. Definition of stage 5 (total RD):</p> <p>Stage 5A: in which the optic disc is visible by ophthalmoscopy (open-funnel detachment);</p> <p>Stage 5B: in which the optic disc is not visible because of retrolental fibrovascular tissue or closed-funnel detachment;</p> <p>Stage 5C: in which stage 5B is accompanied by anterior segment changes (e.g. marked anterior chamber shallowing, iridocorneal adhesions, corneal opacification), suggestin closed-funnel configuration.</p> |

|                          |  |
|--------------------------|--|
|                          | * Additional descriptors of funnel configuration (e.g. open-closed) may be applied if clinically useful.   |
| <b>4. Aggressive ROP</b> | The term aggressive-posterior ROP was used previously to describe a severe, rapidly progressive form of ROP located in posterior zones I or II. Because of increasing recognition that this may occur beyond the posterior retina and in larger preterm infants, particularly in regions of the world with limited resources, the Committee recommends the new term aggressive ROP.* |

Each eye should be classified based on zone, plus disease, stage and extent. If aggressive ROP is present, it should be noted.

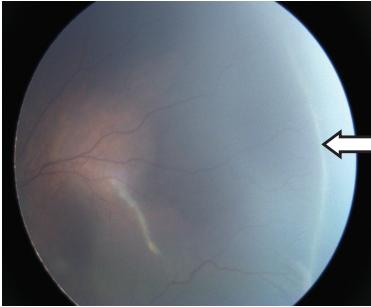
\*Key changes compared with previous ICROP publications.

**Source:**

1. Chiang MF, Quinn GE, Fielder AR, et al. International Classification of Retinopathy of Prematurity, Third Edition. *Ophthalmology*. 2021;128(10):e51-e68
2. Ministry of Health. Management of Retinopathy of Prematurity. Kuala Lumpur: MoH; 2005

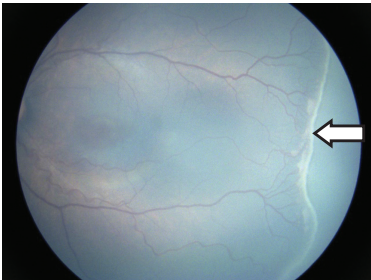
**FEATURES OF RETINOPATHY OF PREMATUREITY**

**a) Stage 1**



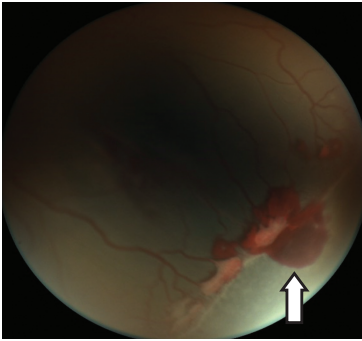
**Demarcation Line**

**b) Stage 2**

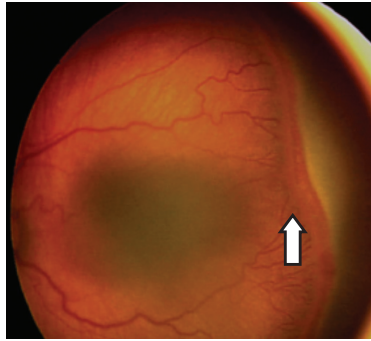


**Ridge**

**c) Stage 3**

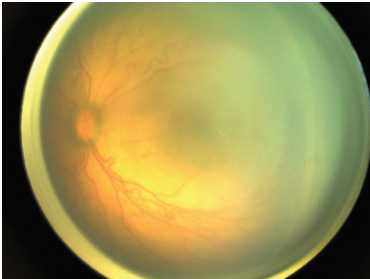


**Extra-retinal fibrovascular proliferation with haemorrhage**



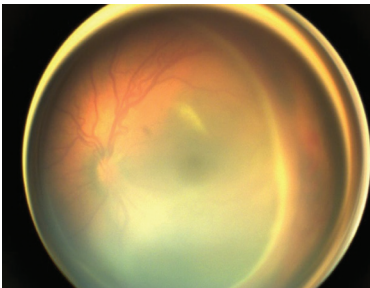
**Thick extra-retinal fibrovascular proliferation**

**d) Stage 4a**



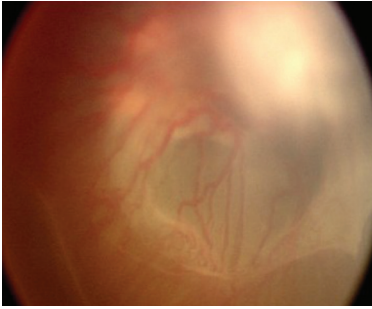
**Partial retinal detachment without fovea involvement**

**e) Stage 4b**



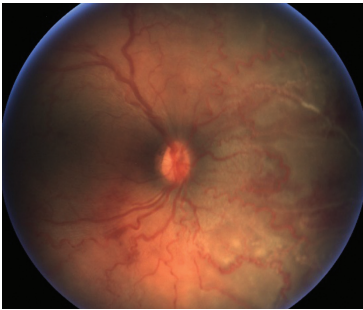
**Partial retinal detachment with fovea involvement**

**f) Stage 5**

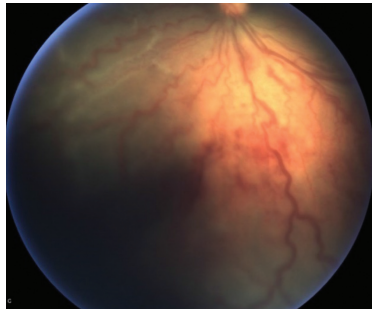


**Total retinal detachment**

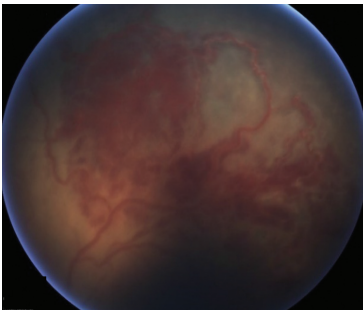
**g) AROP**



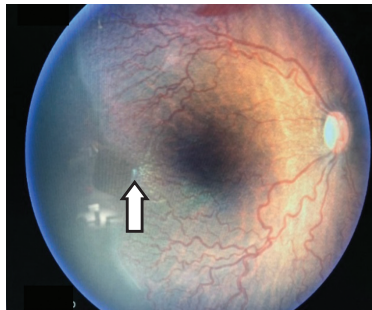
**Posterior pole**



**Mid-peripheral retina**

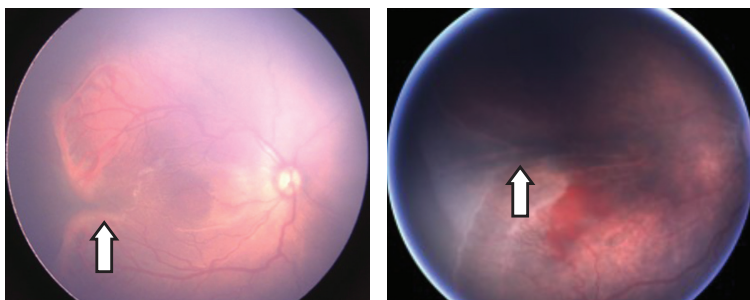


**Peripheral retina**



**AROP with notch**

**h) Additional Features as described in ICROP 2021**



**Presence of notch as indicated by the arrows**



## INDICATIONS OF TREATMENT

### High Risk PreThreshold ROP

Defined into Type 1 and Type 2 to guide the treatment of infants before the development of threshold ROP.

#### Recommended Indications for ROP Treatment

| AROP                                    | PRETHRESHOLD ROP  |   |
|---|---|---|
|   | Type 1 (High Risk)  | Type 2 (Low Risk)   |
| Severe, rapidly progressive form of ROP | <b>Zone I</b> <ul style="list-style-type: none"> <li>• Any stage with plus</li> <li>• Stage 3 without plus</li> </ul> <b>Zone II</b> <ul style="list-style-type: none"> <li>• Stage 2 or 3 with plus</li> </ul> | <b>Zone I</b> <ul style="list-style-type: none"> <li>• Stage 1 or 2 without plus</li> </ul> <b>Zone II</b> <ul style="list-style-type: none"> <li>• Stage 3 without plus</li> </ul> |
| <b>Urgent Treatment</b>                 | <b>Treat within 48 hours*</b>   | <b>Weekly observation</b>   |

\*Subject to stability of the infant

#### Source:

1. Good WV; Early Treatment for Retinopathy of Prematurity Cooperative Group. Final results of the Early Treatment for Retinopathy of Prematurity (ETROP) randomized trial. *Trans Am Ophthalmol Soc.* 2004;102:233-48
2. The Royal College of Ophthalmologists. *Treating Retinopathy of Prematurity in the UK.* London: RCOphth; 2022

## LASER PHOTOCOAGULATION IN ROP

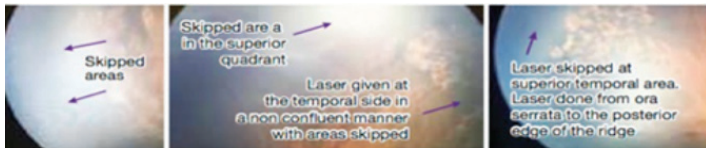### Preparations:

- A. Laser indirect ophthalmoscope (LIO)
- B. 30D or 28D condensing lens
- C. Infant lid speculum
- D. Scleral indenter/squint hook
- E. Subconjunctival mydriacaine (atropine, adrenaline and lignocaine at 1:1:1 ratio) - optional
- F. Topical dilating drops
- G. Topical anaesthesia
- H. Balance salt solution (BSS)
- I. Dexamethasone
- J. Triamcinolone - optional
- K. Cotton buds, cotton balls

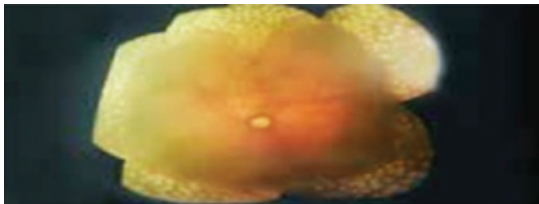
### Steps:

1. Obtain consent from parents/caretakers.
2. Sedate the infant and preferably intubate to ensure no struggling movements during procedure.
3. Treatment must be given in a conducive environment either in NICU or OT.
4. Dilate the pupils even before intubation.
5. Ideally, give subconjunctival mydriacaine 0.05 ml to each eye after the infant is sedated to maintain good pupil dilatation throughout the procedure.
6. Re-examine each eye before starting laser treatment.
7. Set LIO machine at 150 - 200 mW with pulse duration of 100-200 ms and interval of 200 ms.
8. Instil topical anaesthesia into each eye prior to and during the procedure.
9. Start lasering the worse eye first at the avascular area close to ridge at 0.5 - 1.0 spot size spacing with moderate intensity to achieve greyish white (rather than white) burns.
10. Use lower laser parameters and titrate accordingly. Less energy laser power must be used for more anterior retina.
11. Place LIO at arm's length to keep the aiming beam focused.
12. Use BSS to lubricate the cornea. The use of normal saline may cause temporary haziness of the cornea.
13. The laser treatment should cover the entire avascular retina between the ridge and the ora serrata.
14. Do not leave any untreated areas. Some areas are slightly difficult to get access e.g. nasal, superonasal, inferonasal, superotemporal and inferotemporal quadrants. Stand opposite to each quadrant while lasering to gain access to these areas.

15. If there is presence of notching, avoid coming inwards too near to macula as the laser scar might expand and affect the macula region.
16. By the end of treatment session, the laser burns should expand to a near confluent pattern.
17. Always check both eyes again after completion of laser photocoagulation to look out for skip areas.
18. Estimated laser spots at the end of the treatment depends on the zone of ROP (1500 - 2000 laser spots in zone II and  $\leq 1000$  laser spots in zone III for each eye).
19. For post-laser treatment:
  - a. Give orbital floor triamcinolone 10 mg/0.25 ml (optional)
  - b. Start topical corticosteroids and topical antibiotic every four hours for a week
  - c. Review anterior segment of both eyes at day 1 post-laser treatment to look for any epithelial defect, etc.
  - d. Review fundus of both eyes at one-week post-laser treatment



Arrows showing skipped areas post-laser photocoagulation which should be avoided to prevent recurrence of ROP.



Well-lasered retina

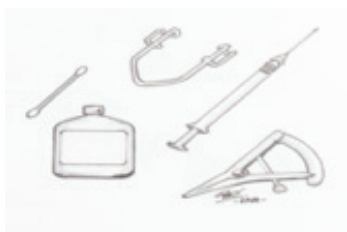
## TYPES AND PROPERTIES OF ANTI-VASCULAR ENDOTHELIAL GROWTH FACTOR

| Anti-VEGF   | Properties  | Pharmacodynamics  | Pharmacokinetics  |
|---|---|---|---|
| <p>Ranibizumab (Licensed for ROP treatment in MoH Facilities)</p> | <ul style="list-style-type: none"> <li>A humanised monoclonal antibody fragment of 48 kDa that has affinity for all isoforms of VEGF</li> <li>Has 5- to 20-fold greater potency than bevacizumab on a molar basis and increased affinity for VEGF, and the advantage of a shorter serum half-life (two hours in adults) which may reduce its potential toxicity in premature infants</li> </ul> | <ul style="list-style-type: none"> <li>Inhibits the human vascular endothelial growth factor A (VEGF-A) by binding to its active forms, thereby preventing ocular angiogenesis by VEGF-A including reduced endothelial cell proliferation, vascular leakage and new blood vessel formation</li> </ul>                               | <p><b>Absorption</b></p> <ul style="list-style-type: none"> <li>Intravitreal implant, T<sub>max</sub>: 26 days (range: 1 to 89 days)</li> <li>Intravitreal injection, T<sub>max</sub>: approximately 1 day</li> </ul> <p><b>Excretion</b></p> <ul style="list-style-type: none"> <li>Total body: cleared primarily by catabolism</li> </ul> <p><b>Elimination half-life</b></p> <ul style="list-style-type: none"> <li>Intravitreal Implant: approximately 25 weeks</li> <li>Intravitreal injection: approximately 9 days (vitreous)</li> </ul> |
| <p>Bevacizumab</p>  | <ul style="list-style-type: none"> <li>A full-length humanised murine IgG monoclonal antibody that has a molecular weight of 149 kD and binds to all VEGF isoforms</li> <li>Has a long half-life in the vitreous (5.6 days in adults), a serum peak level of approximately 2 weeks post-injection and a serum half-life of 21 days in preterm infants</li> </ul>                                | <ul style="list-style-type: none"> <li>A recombinant humanised monoclonal IgG1 antibody, binds to VEGF and inhibits the interaction of VEGF to Flt1 and KDR receptors on the surface of endothelial cells</li> <li>In the process, it prevents the proliferation of endothelial cells and formation of new blood vessels</li> </ul> | <p><b>Distribution</b></p> <ul style="list-style-type: none"> <li>V<sub>d</sub>: 2.9 L; 3.2 L (males); 2.7 L (females)</li> </ul> <p><b>Excretion</b></p> <ul style="list-style-type: none"> <li>Clearance: 0.23 L/day; 2.75 to 5 mL/kg/day</li> </ul> <p><b>Elimination half-life</b></p> <p>20 days (range: 11 to 50 days)</p>  |

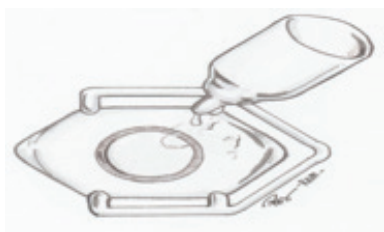
| Anti-VEGF  | Properties   | Pharmacodynamics   | Pharmacokinetics |
|--|--|--|------------------|
| <p><b>Aflibercept</b></p> <ul style="list-style-type: none"> <li>• A 115 kDa recombinant fusion protein that contains the Fc portion of human IgG1 combined with VEGF-binding portions from the extracellular domains of human VEGF receptors 1 and 2</li> <li>• High binding affinity, have an intraocular half-life of 4.8 days in adults and shorter serum half-life than bevacizumab (11.4 days in adults)</li> <li>• Capable of inhibiting all isoforms of VEGF-A and placental growth factor and, after its intravitreal administration, has the ability to penetrate the retina and access the systemic circulation, reducing the systemic levels of VEGF for 12 weeks</li> </ul> | <ul style="list-style-type: none"> <li>• Binds to the VEGF, VEGF-A and placental growth factor, to inhibit their binding to receptor tyrosine kinases and activation of VEGF-A, thereby inhibiting neovascularisation and vascular permeability</li> </ul> | <p><b>Absorption</b></p> <ul style="list-style-type: none"> <li>• Tmax: 1 to 3 days (free aflibercept)</li> <li>• Tmax, pre-term infants: 1 day (free aflibercept)</li> </ul> <p><b>Distribution</b></p> <ul style="list-style-type: none"> <li>• Vd: 6 L (free aflibercept)</li> </ul> <p><b>Elimination half-life</b></p> <ul style="list-style-type: none"> <li>• 5 to 6 days (free aflibercept)<sup>9</sup></li> </ul> |                  |

**Source:** Product insert of the respective anti-vascular endothelium growth factors.

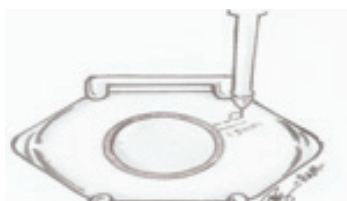### PROCEDURE FOR INTRAVITREAL ANTI-VEGF INJECTION



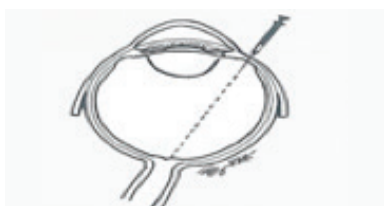**Figure 1:** Instruments required for intravitreal



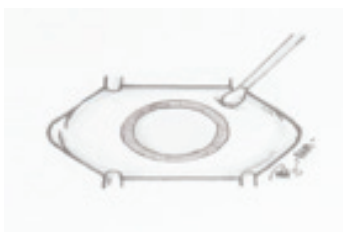
**Figure 2:** Instillation of anaesthetic



**Figure 3:** Top view of needle insertion



**Figure 4:** Side view of needle insertion



**Figure 5:** Cotton bud compression following needle removal

1. Obtain consent from parents/caretakers.
2. Prepare intravitreal set consisting of eyelid speculum, caliper, conjunctival forceps, 1 ml syringe, 27 or 30G 0.5-inch needle, cotton buds and povidone iodine 5% (refer to **Figure 1**).

3. Perform procedure using aseptic technique in a clean place. Infant may require sedation depending on decision of the attending physician.
4. Clean the periorbital skin and conjunctival sac with povidone iodine 5%
5. Drape the eye and insert the speculum.
6. Instil topical anaesthetic drops either proparacaine hydrochloride 0.5% or tetracaine hydrochloride 0.5% (refer to **Figure 2**).
7. Prepare intravitreal ranibizumab 0.2 mg/0.02 ml using aseptic technique.
8. Use 27G/30G needle and inject 1.5 mm posterior to the limbus into mid-vitreous cavity with the needle tip pointing towards the optic disc as indicated by the dotted lines (refer to **Figure 3 and 4**).
9. Remove the needle and compress the wound with cotton bud and instil another drop of antiseptic solution (refer to **Figure 5**).
10. Perform examination using BIO to look for optic nerve perfusion retinal break, RD, haemorrhage and cataract.
11. The speculums are removed and the eyes are irrigated with normal saline solution. Antibiotic eyedrop is given stat to the conjunctival sac and four times per day for 3 - 4 days.
12. Infant is examined again within 24 hours to ensure no development of cataract or early endophthalmitis.

### **SPECIAL PRECAUTION FOR INTRAVITREAL INJECTION IN PREMATURE INFANT**

Eyes of the premature Infant are smaller in size, with absent or immature pars planar and larger/globular crystalline lens relative to the volume of the eye.

**To minimise perforation of the retina or globe and cataract formation, ensure the correct distance, angle and direction of needle insertion.**

## Appendix 11

## SPECIAL EDUCATIONAL SCHOOLS AND INTEGRATION PROGRAMMES FOR PEOPLE WITH VISUAL PROBLEMS

### a. Special Educational Schools for People with Visual Problems

| No. | State           | Pre-School   | Primary School   | Secondary School   |
|-----|-----------------|--|--|--|
| 1   | Kuala Lumpur    | SKPK Jalan Batu<br>Jalan Raja Laut<br>50350 Kuala Lumpur<br>Tel: 03-26921262                       | SKPK Jalan Batu<br>Jalan Raja Laut<br>50350 Kuala Lumpur<br>Tel: 03-26921261                 | SMPK Setapak<br>Jalan Genting Kelang<br>53300 Kuala Lumpur<br>Tel: 03-41493701                               |
| 2   | Johor           | SKPK Princess<br>Elizabeth<br>Lorong 5,<br>Jalan Nong Chik<br>80100 Johor Bahru<br>Tel: 07-2224068 | SKPK Princess<br>Elizabeth<br>Lorong 5,<br>Jalan Nong Chik<br>80100 Johor<br>Tel: 07-2224068 | SMPKV Indahpura<br>Sisiran Indahpura 36/6,<br>Taman Indahpura,<br>81000 Kulai<br>Tel: 07-6625625/<br>6625622 |
| 3   | Pulau Pinang    | SKPK Alma<br>Jalan Bukit Minyak<br>14000 Bukit Mertajam<br>Tel: 04-5082026                         | SKPK Alma (Asrama)<br>Jalan Bukit Minyak<br>14000 Bukit Mertajam<br>Tel: 04-5082026          | -  |
| 4   | Negeri Sembilan | SKPK Seremban<br>Jalan Muthu Cumaru<br>70200 Seremban<br>Tel: 06-7624181                           | SKPK Seremban<br>Jalan Muthu Cumaru<br>70200 Seremban<br>Tel: 06-7624181                     | -  |
| 5   | Sabah           | SKPK Tuaran<br>Peti Surat 50553<br>88200 Putatan<br>Sabah<br>Tel : 088-767202                      | SKPK Tuaran<br>Peti Surat 50553<br>88200 Putatan<br>Sabah<br>Tel : 088-767202                | SMK Badin<br>Peti Surat 149<br>89208 Tuaran<br>Sabah<br>Tel : 088-788357                                     |
| 6   | Sarawak         | SKPK Kuching<br>Jalan Kolej<br>93200 Kuching<br>Tel: 082-2444526                                   | SKPK Kuching<br>Jalan Kolej<br>93200 Kuching<br>Tel: 082-2444526                             | -  |
|     |                 | SKPK Miri<br>Jalan Datuk Muip,<br>Piasau Jaya<br>98000, Miri<br>Tel: 6085-653246                   | SKPK Miri<br>Jalan Datuk Muip,<br>Piasau Jaya<br>98000, Miri<br>Tel: 6085-653246             | -  |
| 7   | Kedah           | -  | SKPK Sungai Petani<br>Mukim Bujang<br>08400 Merbok<br>Kedah Darul Aman                       | -  |



|   |            |   |  |   |
|---|------------|---|--|---|
| 8 | Terengganu | - | SKPK Kuala Terengganu Kampung Kubang Ikan 21080 Kuala Terengganu, Terengganu<br>Tel : 09-6163220 | - |
|   |            | - | SKPK Besut Alor Lintang<br>22200 Kampung Raja Terengganu.<br>Tel : 09-6902430                    | - |

### b. Special Educational Integration Programme at Normal Stream School for People with Visual Problems

| No. | State        | Primary School   | Secondary School   |
|-----|--------------|--|--|
| 1   | Selangor     | SK Kuala Kubu Baru<br>Jalan Sekolah Kuala Kubu Baru<br>44000 Kuala Kubu Baru<br>Tel: 03-60641482     | SMK Kajang Utama<br>43000 Kajang<br>Tel: 03-8733 8414                    |
|     |              | SK Tengku Bendahara Azman 2<br>Lorong Sabah Pandamaran<br>42000 Pelabuhan Kelang<br>Tel: 03-31687155 | SMK Kampung Jawa<br>Jalan Raja Nong<br>41000 Kelang<br>Tel: 03-33734348  |
|     |              | SK Klang<br>Jalan Dato' Hamzah<br>41000 Kelang<br>Tel: 03-33712957                                   | -  |
|     |              | SK Sungai Kantan<br>Jalan Padang Tembak<br>43000 Kajang<br>Tel: 03-87368646                          | -  |
|     |              | SK Seri Utama<br>Jalan Besar<br>43500 Sungai Besar<br>Tel: 03-32242278                               | -  |
|     |              | SK Dato' Maharajalela<br>Jalan Parit Omar<br>45800 Jeram<br>Tel: 03-32648530                         | -  |
| 2   | Kuala Lumpur | -  | SMK St. John<br>Bukit Nanas<br>50250 Kuala Lumpur<br>Tel: 03 - 2078 2846 |

|   |                 |  |  |
|---|-----------------|--|--|
| 3 | Perak           | SK Dato' Laksamana Raja Mahkota<br>Batu 3 1/2, Jalan Maharajalela<br>36000 Teluk Intan<br>Tel/: 05-6221091 | -  |
|   |                 | SK Seri Mutiara<br>Jalan Tunku Abdul Rahman<br>30100 Ipoh<br>Tel: 05-5061925                               | -  |
| 4 | Kedah           | SK Jabi<br>06400 Pokok Sena<br>Tel: 04-7821340   | SMK Tunku Abdul Malik<br>Alor Merah<br>05250 Alor Setar<br>Tel: 04-7319358                             |
|   |                 | -  | SMK Tunku Anum Tunku Abdul Rahman<br>Tok Jalai<br>06000 Jitra<br>Tel: 04-7144960                       |
| 5 | Perlis          | SK Dato' Wan Ahmad<br>01000 Kangar<br>Tel: 04-9762559  | SMK Putra<br>01000 Kangar<br>Tel: 04-9761150   |
| 6 | Pulau<br>Pinang | -  | SMK Alma<br>Jalan Bukit Minyak<br>14000 Bukit Mertajam<br>Tel: 04-5078687                              |
|   |                 | -  | SMK Haji Zainal Abidin<br>Jalan Hamilton<br>11600 Pulau Pinang<br>Tel: 04-2827933                      |
|   |                 | -  | SMK (P) St. George<br>Jalan Macalister<br>10450 Pulau Pinang<br>Tel: 04-2295855                        |
| 7 | Melaka          | SK Air Keroh<br>Lebuh Ayer Keroh<br>75450 Air Keroh<br>Tel: 06-2331146                                     | SMK Padang Temu<br>KM5 Padang Temu<br>45050 Melaka<br>Tel: 06-2820117                                  |
| 8 | Pahang          | SK Indera Mahkota<br>Bandar Indera Mahkota<br>25200 Kuantan<br>Tel: 09 - 5733924                           | SMK Tg. Panglima Perang<br>Tg. Muhammad<br>Bandar Indera Mahkota<br>25200 Kuantan<br>Tel: 09 - 6236594 |
| 9 | Kelantan        | SK Kampong Sireh<br>Jalan Sultanah Zainab<br>15050 Kota Bharu<br>Tel: 09-7418451                           | -  |

|    |            |  |  |
|----|------------|--|--|
| 10 | Johor      | -  | Sekolah Tinggi Muar<br>Jalan Meriam<br>84007 Muar<br>Tel: 06-9521360                               |
| 11 | Sabah      | -  | -  |
| 12 | Sarawak    | Sk Sibu Bandaran No. 3<br>D/A Pejabat Pendidikan<br>Daerah Sibu, Tingkat 6,<br>Wisma Persekutuan, Blok 3,<br>Lot 462, Brooke Drive<br>96000 Sibu<br>Tel/Fax: 084 - 332 512 | SMK Batu Lintang<br>Jalan Kolej<br>93200 Kuching<br>Tel: 082-252579                                |
| 13 | Terengganu | -  | SMK Dato Permaisuri<br>Jalan Dato Permaisuri, Piasau Jaya<br>98000 Miri<br>Tel: 085-659066         |
|    |            | -  | SMK Bukit Besar<br>Jalan Sultan Mohamad<br>20050 Kuala Terengganu<br>Terengganu<br>Tel: 096-236594 |

1. Adopted from *Kementerian Kesihatan Malaysia: Prosedur Operasi Standard: Perkhidmatan Penjagaan dan Rehabilitasi Visual Pesakit Penglihatan Terhadap Perkhidmatan Optometri M/s 54 - 57*

2. For schooling allocations of visually impaired students, refer to the respective State Education Department or District Education Office

3. For updated information on the list of special education schools under Ministry of Education is available at: <http://www.moe.gov.my/pendidikan/khas/sekolah-pendidikan-khas/senarai-sekolah-pendidikan-khas>

**LIST OF ABBREVIATIONS**

|           |  |
|-----------|--|
| AE(s)     | adverse event(s)   |
| AROP      | aggressive ROP   |
| APROP     | aggressive-posterior ROP   |
| Anti-VEGF | anti-vascular endothelial growth factor  |
| BSS       | Balance salt solution  |
| BIO       | Binocular Indirect Ophthalmoscopy  |
| BW        | birth weight   |
| CA        | chronological age  |
| CI        | confidence interval  |
| CPG       | clinical practice guidelines   |
| CPAP      | continuous positive airway pressure  |
| CRYO-ROP  | cryotherapy for Retinopathy of Prematurity   |
| D         | dioptrre   |
| ETROP     | early treatment for Retinopathy of Prematurity   |
| FFA       | fundus fluorescein angiography   |
| G         | gauge  |
| g         | gram   |
| GA        | gestational age  |
| GRADE     | Grading of Recommendations, Assessment, Development and Evaluations  |
| ICROP-3   | International Classification of Retinopathy of Prematurity Third Edition   |
| kg        | kilogram   |
| L         | litre  |
| LIO       | Laser indirect ophthalmoscope  |
| LCPUFA    | Long-Chain Polyunsaturated Fatty Acids   |
| LVS       | lens sparing vitrectomy  |
| MAB       | Malaysian Association for the Blind  |
| MD        | mean difference  |
| MIVS      | micro incision vitrectomy surgery  |
| mg        | milligram  |
| mL        | millilitre   |
| MoH       | Ministry of Health   |
| MoHE      | Ministry of Higher Education   |
| ng        | nanograms  |
| NEC       | necrotising enterocolitis  |
| NICU      | Neonatal Intensive Care Unit   |
| NOS       | Newcastle-Ottawa Scale   |
| NPV       | negative predictive value  |
| OR        | odds ratio   |
| OT        | operation theater  |
| PAR       | persistent avascular retina  |
| PMA       | post-menstrual age   |
| PNA       | post-natal age   |
| PPV       | positive predictive value  |
| RAINBOW   | Ranibizumab versus laser therapy for the treatment of very low birthweight infants with retinopathy of prematurity trial |
| RCT(s)    | randomised controlled trial(s)   |
| RD(s)     | retinal detachment(s)  |
| ROP       | retinopathy of prematurity   |

|        |                                    |
|--------|------------------------------------|
| RR     | relative risk                      |
| SE     | spherical equivalent               |
| SGA    | small for gestational age          |
| TW-ROP | treatment-warranted ROP            |
| UK     | United Kingdom                     |
| USA    | United States of America           |
| VA     | visual acuity                      |
| VEGF   | vascular endothelial growth factor |
| Vd     | Volume of distribution             |
| VI     | visual impairment                  |
| VR     | vitreoretinal                      |
| WMD    | weighted mean difference           |

## ACKNOWLEDGEMENT

The members of CPG DG would like to express their gratitude and appreciation to the following for their contributions:

- Panel of external reviewers who reviewed the draft technically
- Technical Advisory Committee of CPG for their valuable input and feedback
- Health Technology Assessment and Clinical Practice Guidelines Council for approval of the CPG
- Ms. Norharlina Che Zakaria on retrieval of evidence
- Mr. Mohamad Zharfan Bin Ismail for cover design
- Dr. Ahmed Ram Firdause Bin Ridwan Ramdass for illustration on procedure for intravitreal Anti-VEGF Injection
- All those who have contributed directly or indirectly to the development of the CPG

## DISCLOSURE STATEMENT

The panel members of both Development Group and Review Committee had completed disclosure forms. None hold shares in pharmaceutical firms or act as consultants to such firms. Details are available upon request from the CPG Secretariat.

## SOURCE OF FUNDING

The development of the CPG on Management of Retinopathy of Prematurity (Second Edition) was supported financially in its entirety by the MoH.

**MALAYSIAN HEALTH TECHNOLOGY**

**ASSESSMENT SECTION**

Medical Development Division

Ministry of Health Malaysia

Level 4, Block E1, Precinct 1

62590 Putrajaya, Malaysia

e ISBN 978-967-2887-65-2



9 789672 887652